

Impacts of Paracetamol, Malathion and Arsenic or Their Combinations on Liver and Pancreas of Albino Rats.

¹Nashwah I Zaki, ²Manal E.A. El-halwagy, ¹Sahar K. Darwish and ³Amany S.Mohammed

¹ National Organization for Drug Control and Research (NODCAR), Egypt.

²Department of Mammalian Toxicology, Pesticide Central Laboratory, Agriculture Research Center, Giza

³Forensic Medicine and Toxicology department, Faculty of Medicine, Cairo University, Giza, Egypt

Abstract: Current study was undertaken to evaluate the impact of repeated co-exposure of the widely used analgesic-antipyretic drug Acetaminophen (Paracetamol), Malathion (organophosphates pesticides), and metalloid (Arsenic) on the functions of the liver and pancreas of male albino rats. Eighty male albino rats weighing 140-160g were orally treated with Acetaminophen (100 mg/kg b.w), Malathion (30 mg/kg b.w) or Arsenic (1.5 mg/kg b.w) individually and in-combination for 28 days. Biochemical results revealed that all treatments under investigation showed significant increase in serum aspartate aminotransferase (AST) alanine aminotransferase (ALT) and amylase activities, as well as fasting glucose levels. Lipase recorded fluctuation in its activity according to treatment group, whereas cholinesterase activity (ChE) showed non-significant changes except for malathion treatment. In contrast, paraoxonase (PON1) and insulin activities were significantly declined after single and combined treatments at ($P < 0.05$). Histopathological changes in liver and pancreas tissues among all treated groups were recorded. These physiological and pathological observations were more prominent in combined treatments. In conclusion, association of environmental factors including drug therapeutic dose and pollutants might lead to different unexpected types and levels of toxicities.

Key words: Analgesic drugs, metalloid, organophosphate, liver, pancreas, histopathology

INTRODUCTION

It is well established that people are exposed to a diverse and dynamic mixture of environmental and occupational stressors as a routine part of their existence. Up until recently, about 95% of all chemical toxicity studies were performed on individual chemicals (Simmons, 1995; Groten *et al.*, 1999). The biological activity of a chemical may be modified through prior or simultaneous exposure of a test organism to another chemical agent and such interactions might result in a potentiation, summation, or reduction of the ultimate effect of the chemical (Eaton and Klaassen, 2001).

Acetaminophen (Paracetamol) is one of the most common antipyretic and analgesic used all over the world as its easily accessible over the counter and present in so many different pharmaceutical agents. The words Acetaminophen and Paracetamol (APAP) both come from the chemical names for the compound N-acetyl-para-aminophenol and para-acetyl-amino-phenol. Paracetamol poisoning has primarily been associated with hepatotoxicity including fulminant hepatic failure. Hyperamylasemias is frequent in patient with paracetamol poisoning whereas clinical acute pancreatitis (AP) rarely occurs (Schmidt and Dalhoff, 2004). The potential of hepatotoxicity differs for each individual and depends essentially on associated risk factors which could lead to a severe hepatotoxicity even at therapeutic doses (Seirafi *et al.*, 2007). Malathion is one of the most extensively used organophosphorus pesticides applied in agriculture, mosquito eradication, control of animal ectoparasites and human body lice (Barr *et al.*, 2005). The widespread use of Malathion has raised concern over its potential to cause unwanted health effects in humans, animals and birds. Malathion inhibits cytochrome P450 monooxygenases and has the potential to alter pharmacokinetic profiles of therapeutic agents that are metabolized in the liver (Babu *et al.*, 2006). Preliminary studies have reported that OPs caused liver damage (Gupta *et al.*, 1992; Bachowski *et al.*, 1997). It has been reported that malathion is one of the most pronounced organophosphates responsible for OP-induce pancreatitis (Gokcimen *et al.*, 2007; Harputluoglu *et al.*, 2003; Hsiao *et al.*, 1996). Glucose metabolism disturbances have been observed with exposure to Ops including Malathion. These disturbances include insulin and blood glucose concentration, as well as changes of glucose metabolism enzymes (Abdollahi *et al.*, 2004; Pournourmohammadi *et al.*, 2005). Arsenic (As) is a naturally occurring toxic metalloid found in the environment in both inorganic and organic forms. Inorganic As (iAs) is the predominant form of As in surface and underground water reservoirs (Paul *et al.*, 2007). Millions of individuals worldwide are exposed to drinking water contaminated with inorganic Arsenic mainly from natural mineral deposits (Smedley and Kinniburgh, 2002). Increasing evidence indicates that inorganic Arsenic may cause cancers of the kidney, prostate and liver. It also causes cardiovascular disease, diabetes, developmental and reproductive effects (NRC, 1999; Waalkes *et al.*, 2000; Navas-Acien *et al.*, 2005, 2006; Benbrahim-Tallaa

Corresponding Author: Manal E.A. Elhalwagy, Associate Professor of Biochemistry Mammalian and Aquatic Toxicology Department, Pesticide Central Lab. Agriculture Research Center Giza 12618, Egypt
E-mail: melhalwagy62@yahoo.com; Mob: 202-0124474988

and Waalkes, 2008). Furthermore, it becomes evident that even low level of Arsenic may pose a significant health risk to human especially for diabetes mellitus (NRC, 1999; Navas-Acien *et al.*, 2008). Although Arsenic content of the consumed water in Egypt is below the maximum drinking water level allowed by World Health Organization (WHO, 2004) is 10 µg /L, hair Arsenic levels were above the allowable values in 45% of apparently health Egyptian (Saad and Hassanien, 2001).

Public interest in the cumulative health effects of environmental exposures continues to grow as information increases about the potential for multiple exposures to variety sources. These sources include pesticide applications and industrial releases, as well as pharmaceuticals materials. Cumulative risk assessment provides the integrating foundation for linking these factors together, to produce an overall risk picture and better inform health protection programs (Lamberta *et al.*, 2011). The purpose of the present study is to throw light into some physiological and histological changes of liver and pancreas of albino rats exposed to repeated doses of either individual or combined treatments of Paracetamol, Malathion and Arsenic.

MATERIALS AND METHODS

Chemicals:

Paracetamol Drug:

tablets (Pharko-Egypt). Each tablet contains 500 mg Paracetamol, was purchased from local pharmacy. The therapeutic dose for rat was (100 mg/kg) a non toxic dose according to Naziroğlu *et al.*, 2009. **Malathion** [S-(1, 2-dicarbethoxy) ethyl-0, 0-dimethyl-phosphorodithioate] 57% EC (Awida-Egypt) and was purchased from local market. The dose chosen was (30 mg/kg/day which equivalent to ADI_{x100}= NOEL). **Sodium arsenite** (NaAsO₂) was obtained from Sigma Chemical Company. The **arsenic** dose was 1.5 mg/ kg body wt /day which was within the range of LD50 of a 70-Kg body wt. human (1-4 mg/Kg) and lesser than 1/25 of LD50 of rats (40mg/kg) according to Mukherjee *et al.*, 2003 and 2004.

Experimental Design:

Eighty male albino rats weighing 140-160 g were supplied by National Organization for Drug Control and Research animal house. They were housed in wire cages with natural ventilation, illumination and allowed free water as well as standard diet. The initial body weights and weekly changes were recorded. All animals were treated according to the standard procedures laid down by OECD (1992) guidelines 407 repeated dose 28 days oral toxicity study in rodents. After one week of acclimatization period, animals were randomly assigned into eight main groups, each one comprises of ten rats. All rats received daily oral treatments dissolved in distilled water via a gastric tube over a total period of 28 days. **Control Group** animals received a daily volume of distilled water (1ml /100g body weight). **Paracetamol Treated Group (APAP)**: animals received a dose of paracetamol 100 mg/kg body weight. **Malathion Treated Group (MA)**: animals received malathion 30 mg/kg body weight. **Arsenic Treated Group (As)**: animals received sodium arsenite 1.5 mg/kg body weight. **Paracetamol-Malathion Treated Group (APAP+MA)**: animals were received paracetamol dose (100 mg/kg body weight) and malathion (30mg/kg body weight) consecutively. **Paracetamol-Arsenic Treated Group (APAP+As)**: animals were received paracetamol dose (100 mg/kg body weight) and sodium arsenite (1.5 mg/kg body weight) consecutively. **Malathion-Arsenic Treated Group (MA+As)**: animals were received malathion (30mg/kg body weight) and sodium arsenite (1.5 mg/kg body weight) consecutively. **Paracetamol, Malathion-Arsenic Treated Group (APAP+MA+As)**: animals were received paracetamol dose of 100 mg/kg body weight, Malathion (30 mg/kg body weight) and sodium arsenite (1.5 mg/kg body weight) consecutively.

At the end of experimental period, fasting blood samples were collected from retro-orbital plexus (Schalm, 1986). Blood serum was separated by centrifugation at 1000 x g and 4°C per ten minutes. Then serum was kept at -40 °C for further biochemical analysis.

Biochemical Analysis:

Serum aspartate aminotransferase (AST) and alanine aminotransferase (ALT) activities were determined using the method of Reitman and Frankel, 1957. Cholinesterase activity (ChE) in serum was determined using a procedure described by (Ellman *et al.*, 1961). Paraoxonase PON1 was measured by adding 6.6 µl of serum to 1 ml Tris/HCl buffer (100 mmol/l, pH 8.0, Sigma-Aldrich) containing 2 mmol/l CaCl₂ and 5.5 mmol/l paraoxon (O, O-diethyl-O-p-nitrophenylphosphate) The rate of P-nitrophenol generation was determined with spectrophotometer Spectronic (USA) at 405 nm and the PON1 activity was expressed in U/I according(Furlong *et al.*, 1989). Serum glucose level was determined according to Trinder (1959) using the commercial diagnostic kit of Stanbio Co., Spain. Total insulin level was determined according to Bates (1983) using radioimmunoassay kit of DPC. Co. American, the Coat -A- Count Insulin procedure is a solid phase radioimmunoassay, where in I125 labeled insulin competes for a fixed time with insulin in serum sample for sites on insulin specific antibody, counting the tubes on gamma counter then yields a number, which converts by way of calibration curve to a measure the insulin present in serum. Lipase activity was determined using kinetic method according to Junge *et al.*, 1983. Amylase activity was estimated according to Lent (1986).

Histopathological Studies:

Livers and Pancreases tissues were obtained immediately and fixed in 10 % formalin- solution. Serial sections were prepared at 4 μ , then, stained with haematoxylin and eosin (H&E) according to the method of Mussa *et al.*, 1984. Sections were examined by light microscope.

Data Analysis:

The obtained data from the biochemical analysis of different groups were expressed as mean \pm standard error (X \pm SE) and analyzed using one-way analysis of variance (ANOVA) followed by Duncan and Dunnett t (2-sided) post hoc multiple comparison tests, the significant level was accepted at P<0.05 using the SPSS- PC computer software package version 17. Joint action analysis for treatments was calculated using “relative interaction index” (RII) according to Mansour *et al.* (2001).

Results:**Biochemical Results:**

Data presented in Table (1) showed that animals intoxicated with APAP, MA and As individually or in combination with each other induced significant elevation in the liver enzymes biomarkers AST and ALT versus control. Pronounced elevations in the activities of liver enzymes biomarkers were recorded in combined intoxicated groups APAP+ MA+As with a percent changes 157% and 128 % respectively from the control. On the other hand, inhibition in serum cholinesterase activity was recorded in all groups intoxicated with MA individually or in combination with both APAP and As. This inhibition was significant only among MA treatment; while the other treatments induced non-significant elevation in comparison to the control at (P<0.05). Significant inhibition in PON1 activity was recorded among all treatment groups Table (1). Repeated doses of APAP, Malathion and Arsenic either individually or in- combination induced significant increase in fasting blood sugar (Table 2). Simultaneously, there were significant reduction in insulin activity was recorded in all treated groups versus control group at (P<0.05). It should be noted here that Lipase activity dose not has a significant changes from control in groups intoxicated individually, however a pronounced significant reduction was recorded in combination between APAP+MA and APAP+AS+MA. Pointed to amylase increases in its activity was recorded in all treated groups as compared to control (Table 2), where the percentage of the maximum changes shown by combined treatments MA+As (35.9 %) and APAP+MA+As (34.8%).

Table 1: Effect of paracetamol, malathion and arsenic and their combination on some liver biomarkers in serum of albino rats after 28 days of exposure.

Parameter				
Groups	AST (U/L)	ALT (U/L)	ChE (μ mol/SH/hr/ml)	PON1 (U/L)
C	23.72 \pm 0.48a	18.83 \pm 1.54a	438.87 \pm 13.30bcd	24.56 \pm 1.17d
APAP	36.30 \pm 0.32c	42.94 \pm 0.80d	478.21 \pm 9.25d	18.83 \pm 0.51c
MA	32.32 \pm 0.25b	35.20 \pm 0.24b	298.99 \pm 11.48a	13.84 \pm 1.31a
As	34.72 \pm 0.34c	39.85 \pm 0.57c	466.35 \pm 25.20cd	15.13 \pm 1.25ab
APAP+ MA	53.25 \pm 0.75f	40.62 \pm 0.57c	428.387 \pm 18.53bc	15.49 \pm 0.94ab
APAP+ As	42.05 \pm 0.36d	40.39 \pm 0.29c	435.417 \pm 10.73bcd	14.18 \pm 1.06a
MA +As	46.71 \pm 0.35e	40.90 \pm 0.61cd	417.184 \pm 16.52b	17.78 \pm 0.63c
APAP+MA+ As	54.04 \pm 1.55f	48.40 \pm 0.72e	462.808 \pm 9.00bcd	13.90 \pm 0.56a

No. of animals/group=10 rats

* Significant difference against control at P<0.05

Groups have the same letter mean non significant at P < 0.05

Groups have different letters means significant at P < 0.05

Table 2: Effect of paracetamol, malathion and arsenic and their combination on some biomarkers of pancreas in serum of albino rats after 28 days exposure.

Parameter				
Groups	Glucose (mg/dl)	Insulin (U/L)	Lipase (U/L)	Amylase (U/L)
C	79.17 \pm 3.71 ^a	6.49 \pm 0.40 ^c	58.30 \pm 4.17 ^b	651.36 \pm 13.01 ^a
APAP	113.84 \pm 5.22 ^{cd}	4.91 \pm 0.07 ^b	57.81 \pm 1.98 ^b	775.92 \pm 14.38 ^{bc}
MA	96.33 \pm 1.0 ^b	4.80 \pm 0.07 ^{ab}	60.02 \pm 2.38 ^b	722.89 \pm 21.30 ^{ab}
As	113.74 \pm 4.57 ^{cd}	4.50 \pm 0.08 ^{ab}	64.71 \pm 2.71 ^{bc}	766.82 \pm 18.27 ^{bc}
APAP+ MA	99.30 \pm 5.32 ^b	4.36 \pm 0.13 ^{ab}	38.76 \pm 1.82 ^a	828.19 \pm 18.05 ^{cd}
APAP+ As	121.79 \pm 0.75 ^d	4.36 \pm 0.01 ^{ab}	57.58 \pm 2.12 ^b	790.02 \pm 20.77 ^c
MA +As	111.49 \pm 4.6 ^{cd}	4.76 \pm 0.21 ^{ab}	70.96 \pm 2.04 ^c	884.98 \pm 20.10 ^d
APAP+MA+ As	109.65 \pm 1.36 ^c	4.25 \pm 0.10 ^a	33.44 \pm 1.75 ^a	878.27 \pm 32.55 ^d

No. of animals/group=10 rats

* Significant difference against control at P<0.05

Groups have the same letter mean non significant at P < 0.05

Groups have different letters means significant at P < 0.05

Joint Action Analysis:

Pinpoint to potential health hazard of tested combined treatment co-exposure. Joint action analysis was carried out using the final data obtained from biochemical parameters. The numbers of potentiated biochemical indices obviously recorded in MA+AS and APAP+MA+AS groups. However there is a recorded antagonistic effect in APAP+As group. On the other hand, equilibrium between potentiating and antagonism effect on biochemical parameters was reported in APAP+MA (Table 3).

Table 3: Joint action analysis for paracetamol, malathion and arsenic co-exposure after 28 days of exposure on different biochemical parameters.

Parameters	AST	ALT	ChE	PON1	Glucose	Insulin	Lipase	Amylase
Groups								
APAP+MA (RII)	1.55(P)	1.04(P)	1.10(P)	0.95(A)	0.87(A)	0.90(A)	0.66(A)	1.14(P)
APAP+As (RII)	1.18(P)	0.98(A)	1.11(P)	0.84(A)	1.07(P)	0.93(A)	0.94(A)	0.86(A)
MA+ As (RII)	1.39(P)	1.09(P)	0.88(A)	1.23(P)	1.06(P)	1.02(P)	1.14(P)	1.22(P)
APAP+MA+As (RII)	1.57(P)	1.23(P)	1.12(P)	0.87(A)	1.02(P)	0.9(A)	0.55(A)	1.02(P)

Aspartate Aminotransferase (AST); Alanine Aminotransferase (ALT); Cholinesterase (ChE); Paraoxonase (Pon1); RII: relative interaction index, where: RII > 1 means "Potentiate" (P); RII < 1 means "antagonistic" (A); RII = 1 means "no observed effect"

Histopathological Findings:

Photomicrographs of hepatic tissues of rat are illustrated in Plate (1) showed changes in the liver tissues of rats treated with different environmental agents for 28 days. Control liver tissues showed normal liver architecture. The central vein and the cords of hepatocytes were radiating from it. The hepatocytes were polygonal in shape; contain vesicular nuclei and acidophilic cytoplasm. Liver cells cords entrap liver blood sinusoids between them, these sinusoids were lined by sinusoid lining cells (Fig. a). Liver of APAP treated group, revealed mild to moderate toxicity where in 50% of the population, portal areas with periportal inflammatory infiltrates, mainly lymphocytes, together with bile ducts proliferation. Hepatocytes with deeply eosinophilic cytoplasm; nuclei with reduction in size, this is beside focal necrotic areas. Meanwhile in 25% of the animals within the group, interlobular hemorrhage; fibrosis; focal necrotic areas and signs of apoptosis were observed (Fig. b). Meanwhile, liver tissues of MA treated group, mild to moderate pathological lesions was detected, in form of few dilated central veins; edema; mild fibrotic changes in portal areas with thickened hyalinized portal veins. Also, there were areas of dilated sinusoids besides focal inflammatory aggregates within lobules; many hepatocytes with vacuolated cytoplasm and hypertrophied nuclei. Hyaline bodies formation were occasionally seen (Fig. C₁& C₂). Moderate signs of liver toxicity were observed in the group of rats treated with AS individually, where the majority of central veins with lacerated walls; focal areas of dilated sinusoids and prominent bile canaliculi were seen as well as portal areas with bile ductules proliferation, together with perivascular inflammatory infiltrates. Hepatocytic cytoplasm was still with vesicular nuclei (Fig.d). Co administration of Paracetamol and Malathion (APAP+MA) produce more toxic impacts on liver cells, in form of dilated congested vasculature; few restricted portal areas; proliferated vonkupffer cells; prominent bile canaliculi; hepatocytes with homogenous eosinophilic cytoplasm and hypertrophied nuclei were seen (Fig.e). Meanwhile, Paracetamol with Arsenite (APAP+AS) treatment produced sever toxicity to liver cells, where many focal necrotic areas, hyaline bodies' formation; hepatic steatosis and injured vasculature was observed (Fig .f). In Malathion –Arsenite treatment (MA+As), portal areas with edema and thick portal vein; mild fibrotic changes; congested dilated sinusoids with proliferated vonkupffer cells was seen. Also, vacuolated hepatocytes with hypertrophied nuclei were observed (Fig.g). The most sever toxic impacts were observed in co-administration of the three agents (APAP+MA+As). Multifocal necrotic areas, many hyaline bodies formation and many expanded portal areas with proliferated bile ducts were seen (Fig. h).

On the other hand, photomicrograph of pancreatic tissues of rat were illustrated in Plate (2) showed changes in pancreatic tissues of rats treated with different environmental agents for 28 days. Pancreatic tissues of the control showed acini of the pancreas with their pyramidal cells and each cell has a round nucleus with the characteristic basal basophilia and apical acidophilia. The acini were divided by thick connective tissue septa into groups. Islets of Langerhans were seen as group of round cells scattered between the pancreatic acini and rich in blood supply (Fig. a). Pancreatic tissues of APAP treated rats showed intact islets were observed, however mild pancreatitis in form of perivascular infiltration of leukocytes, mostly polymorph accompanied with hemorrhagic areas in pancreatic tissues, this is beside occasional destruction of acini outside the islets (Fig. b). Pancreatic tissues of MA treated rats, revealed mild to moderate pathological alterations in form of dilated congested vascular channels with thick hyalinized wall and few fibrotic bands extended between pancreatic tissues. hyperplasia of lymphatic vessels with inflammatory reaction and mast cells were seen. Pancreatic islets showed mild lesions in form of reduction in size and cellularity of some islets, accompanied with vacuolation in and between islets cells. Inspissated pancreatic ducts were also observed (Fig.c₁&c₂).IN pancreas of As treated animals, most lesions were seen in pancreatic islets, where reduction in cellularity and size which compensated by few hypertrophied islets. Congested, edematous islets were also detected. Thickened pancreatic septa with mast cells were frequently observed (Fig.d). pronounced toxicity sings were observed in (APAP+MA) treated animals, many islets showed reduction in size and cellularity as well as in number; congestion; inter and interavacuolation were detected in many islets. Congested vasculature together with interstitial congested edematous areas were detected, however no inflammation or acini damage was seen. (Fig.e). Pathological

observations of pancreatic tissues in (APAP+AS) treated rats showed, hyperplasia of some islets; inspissated pancreatic ducts; this is beside edematous congested and inflammatory area were detected accompanied with inter and intralobular fibrosis. IN 50 % of cases pyknotic nuclei of pancreatic acinar cells were detected. (Fig.f). co-exposure of (MA+AS) produce sever damage to pancreatic tissues where reduction in cellularity and size of many islets were noticed; focal areas of injured acini with their pyknotic nuclei. Focal areas of interstitial inflammation and mast cells aggregates together with thickened vasculature were seen. (Fig.g). The most toxic impacts on pancreatic tissues was seen after the administration of the three materials (APAP+MA+AS). Many hypertrophied islets; thickened congested blood vessels together with perivascular inflammation with mast cells and fibrotic interstitial tissues occurrence (Fig. h).

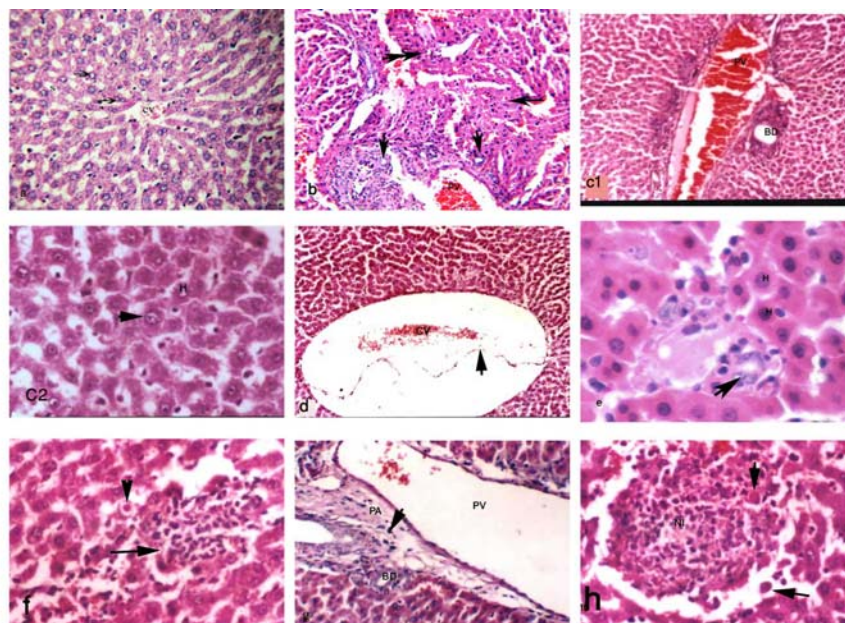


Plate. 1: Liver tissue of albino rat treated with different environmental agents for 4 weeks using H&E; (a) liver tissue of control albino rat, demonstrating central vein (CV), intact hepatocytes (Arrow), and sinusoids (S) X: 200.; (b) APAP gp, showing congested portal vein (PV), proliferated bile ducts (Arrow head), necrotic area (Double arrow) X: 200.; (c₁) MA gp, demonstrating portal area (PA), with congested portal vein (PV), bile duct (BD), X: 200.; (c₂) MA group focusing on hepatocyte (H) with hypertrophied nuclei (Arrow head), X: 400.; (d) As gp, showing dilated central vein (CV), with lacerated wall (Arrow head), X: 200.; (e) APAP+MA gp, showing prominent bile ductule (arrow), hepatocytes with apoptotic nuclei and eosinophilic cytoplasm X: 400.; (f) APAP+As gp, showing congested and dilated sinusoids (S), with necro-inflammatory area (Arrow) and hyaline body formation (Arrowhead). X: 200.; (g) MA+As gp demonstrating edema in portal area (PA), dilated portal vein (PV), mast cell (Arrow head), and bile duct (BD), X: 400.; (h) APAP+MA+As gp necro-inflammatory area (NI) with many hyaline bodies, X: 400.

Discussion:

Organisms in the environment often experience many stressors simultaneously, including those of a physical, biological and chemical nature. We aimed in the present study to investigate the effect of individual treatment with each of APAP, MA and As for 28 days in comparison to their combinations. Animals treated with daily dose of APAP, MA and As for 28 days induced elevation in liver enzymes biomarkers AST and ALT. The dose of APAP used in the present study (100 mg/kg) which considered as non toxic therapeutic dose, its administration in repeat manner resulted in potentiating liver toxicity. The elevated aminotransferases activities were considered indicative criteria of APAP induced hepatic damage in rats (Yanpallewar *et al.*, 2003). As well as the possibility that a nontoxic dose of APAP could be unsafe when administered repeatedly (Kim *et al.*, 2009). Meanwhile, Bashir *et al.*, 2006 reported the increase in transaminases activity in rat exposed to Arsenic could be due to possible leakage of enzymes across damaged plasma membranes or the increased synthesis of enzymes by the liver. Though the liver plays an important role in metabolic processes and detoxification of many xenobiotics, chronic exposure to metals like Arsenic may lead to accumulation of metal in the liver and

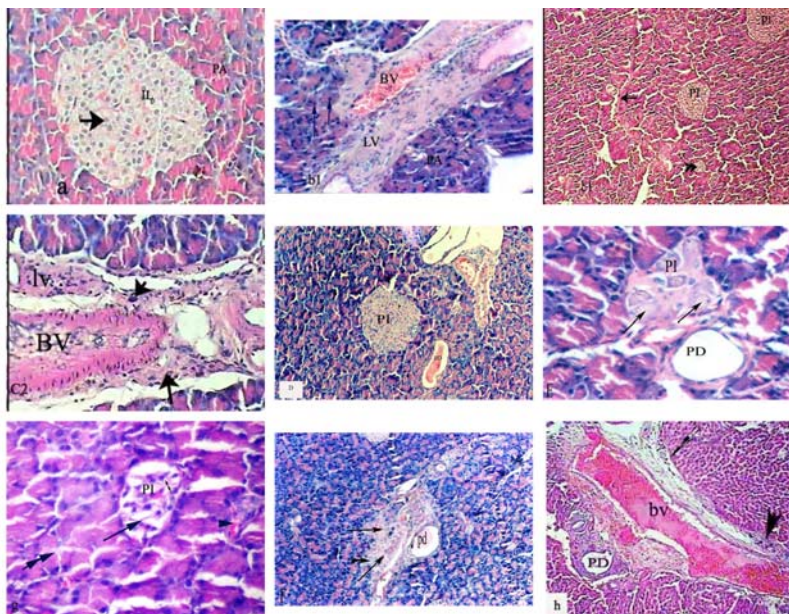


Plate. 2: Pancreatic tissue of albino rat treated with different environmental agents for 4 week using H&E; (a) pancreatic tissue of control albino rat showing intact pancreatic islet(PI), and pancreatic acini(PA) X: 400.; (b) APAP gp. focusing on destructed pancreatic acini, with pyknotic nuclei (Arrow), thickened lymphatic vessel(LV), congested blood vessel (BV)., X: 200.; (c1) MA gp. showing islet with reduction in size and cellularity (PI), fibrotic band (Arrow)., X: 100.; (c2) MA gp. showing congested blood vessel (BV), lymphatic vessel (LV), inflammatory cells aggregates(Arrow) X: 400.; (d) As gp. showing hyperplasia of pancreatic islet (PI), inspissated pancreatic duct (PD) X: 200.; (e) APAP+MA gp showing pancreatic islet with edematous cells, pancreatic duct (PD), pyknotic nuclei of pancreatic acinus (Arrow head)., X: 200.; (f) APAP+As gp showing edematous area, congested blood vessel (BV), inflammatory cells aggregates(Arrow) X: 200.; (g) MA-As gp demonstrating pancreatic islet (PI), vacuolation in cell, and between cells (Arrow) X: 200.; (h) APAP+MA+As gp. Demonstrated

cause pathological alterations. Intoxication with organophosphorus insecticides induced elevation in plasma ALT and AST that may result from leakage of enzymes from the damaged tissues of liver (Tos-luty *et al.*, 2003). The previous findings were supported with histopathological studies where different degrees of damage were reported in individual intoxicated groups but it was pronounced in combined intoxicated groups. The present study showed reduction in AChE activity pronounced among malathion treated groups. previous studies showed that the primary mechanism of action and most acutely life threaten effect of OPs insecticides are related to accumulation of acetylcholine within the cholinergic synapses due to inhibition of acetyl cholinesterase by active oxon metabolites (Karanth *et al.*, 2006; Gokcimen *et al.*, 2007; Elhalwagy and Zaki, 2009). Also, we noticed that the activity of cholinesterase was not altered by APAP or Arsenic exposure. These results agree with Hernandez's *et al.* 2009 who demonstrated that AChE activity did not change due to As toxicity. While it contrast to other studies by Patlolla and Tchounwou, 2005; Ali *et al.*, 2010 reporting decreased cholinesterase activity in response to chronic arsenic exposure in rats and human respectively. The reasons for this discrepancy might be attributed to the differences in study species, levels of arsenic exposure and durations between the studies. Regarding to the significant increase in fasting glucose level concurrent with marked inhibition in insulin in the current study, It might be contributed to oxidative stress induced by APAP, Malathion and or Arsenic hepatotoxicity through generation of reactive oxygen species (Ita *et al.*, 2009; Kostopnagiotou *et al.*, 2009; Youshikawa *et al.*, 2009), which in turn function as signaling molecules to activate a number of cellular stress-sensitive pathways linked to insulin resistance and decreased insulin secretion (Izquierdo-Vega *et al.*, 2006). It has also been reported that oxidative stress was involved in the cytotoxicity of arsenic (Banerjee *et al.*, 2009; Fu *et al.*, 2010). Arsenic-induced oxidative stress has been suggested to be due to the generation of NO, which could cause DNA damage and activate poly (ADP-ribose) polymerase, a major cause of islet cell damage in diabetes (Inada *et al.*, 1995; Mukherjee *et al.*, 2003). Also, we suggested that APAP, MA and AS might induce pathological changes in pancreas architecture including beta cell structure result in selective alteration in its function which has been evident by our histological findings and run parallel with early findings by Hinson *et al.*, 1984 and Ferguson *et al.*, 1990. Several observations indicate that, organophosphate pesticides or Arsenic affect glucose homeostasis (Pournourmohammadi *et al.*, 2005, 2007).

Hyperglycemia associated with significant inhibition in insulin activity was detected in the present study, numerous laboratory studies have demonstrated that iAs and some As compounds suppress insulin production by pancreatic β -cells, and modulate glucose uptake by various cells, including adipocytes and myocytes (Navas-Acien *et al.*, 2006; Paul *et al.*, 2007). Inhibition in PON1 activity recorded in the present study could be contributed to oxidative stress induces by different treatments used. paraoxonase activity correlated positively with antioxidant protein-SH and negatively with oxidant lipid hydroperoxides indicating itself as an oxidative stress marker. The metabolic activation of pesticides to highly reactive intermediates might account for the decrease in PON1 activity, as this enzyme can be inactivated by these compounds after oxidative stress challenge (Hernandez *et al.*, 2004; Araoud *et al.*, 2010). some paraoxonase genes might have important implications for a novel and potentially useful biomarkers of Arsenic risk (Liao *et al.*, 2009). Regarding to amylase activity as it considered as a marker of pancreas function, The current results of serum amylase activity introduced further indication that APAP, Malathion and Arsenic administration caused pancreatic dysfunction. Hyperamylasaemia is accepted as a sign of pancreatic diseases in routine clinical use and may simply reflect direct APAP-induced pancreatotoxicity. Mechanisms that the toxin induced pancreatitis might contribute to some potential mechanisms include pancreatic duct obstruction, cytotoxic and metabolic effects, as well as accumulation of toxic metabolite or intermediary and hypersensitivity reactions (Badalov *et al.*, 2007; Balani and Grendell, 2008). Selective and graduated potentiated effects were detected among the concurrent exposure of Acetaminophen, Malathion and arsenic.

Joint action analysis confirms that toxic effects of environmental toxicants are modified by exposure to Acetaminophen containing drugs or other pollutants. The highest antagonistic effect on biochemical parameters were recorded in APAP+As group, while, an equilibrium between potentiating and antagonism effect on biochemical parameters was reported in APAP+MA. Parallel to our work Manimaran *et al.*, 2010b concluded that co-exposure to arsenic and acetaminophen may be less hazardous than their independent exposure in rats. Also, he demonstrated that arsenic preexposure increased the susceptibility of rats to hepatic oxidative stress induced by the lower dose of acetaminophen, but reduced the oxidative stress induced by the higher dose (Manimaran *et al.*, 2010a). however, the combined treatment of Malathion and Arsenic induced more potentiated effects among binary treatments this may be supported by Siller *et al.* (1997) who demonstrated that arsenite pretreatment increased the acute toxicity of parathion and further decreased the inhibitory effect of parathion on brain AChE activity, whereas the joint administration of arsenite and parathion produced effects similar to those of arsenite.

In conclusion, the concomitant exposure Malathion and Arsenic appearing more hazardous to selective biochemical variables related to liver and pancreas and could potentiate Paracetamol hepatopancreatic toxicity. Obviously, the findings of our study focus on the need to evaluate the potential effects of other commonly encountered environmental pollutants.

REFERENCES

- Abdollahi, M., M. Donyavi, S. Pournourmohammadi, M. Saadat, 2004. Hyperglycemia associated with increased hepatic glycogen phosphorylase and phosphoenolpyruvate carboxykinase in rats following subchronic exposure to Malathion, Comp. Biochem. Physiol. C. Toxicol. Pharmacol., 137: 343-347.
- Ali, N., A. Hoque, A. Haque, K.A. Salam, R. Karim, A. Rahman, Kh. Islam, A.Z. Saud, M.d. Abdul Khalek, A.A. Akhand, M. Hossain, A. Mandal, R.Md. Karim, H. Miyataka, S. Himeno, Kh. Hossain, 2010. Association between Arsenic exposure and plasma cholinesterase activity. A population based study in Bangladesh. Environ Health., 9: 36. doi.10.1186/1476-069X-9-36.
- Araoud, M., F. Neffeti, W. Douki, M.F. Najjar, A. Kenani, 2010. Paraoxonase 1 correlates with butyrylcholinesterase and gamma glutamyl transferase in workers chronically exposed to pesticides. J occup Health, 52(6): 383-8.
- Babu, N.S., J.K. Malik, G.S. Rao, M. Aggarwal, V. Ranganathan, 2006. Interactive alterations of Arsenic and Malathion in the disposition kinetics of pefloxacin. Arch Environ Contam Toxicol., 50(4): 587-93.
- Bachowski, S., K.L. Kolaja, Y. Xu, C.A. Ketcham, D.E. Stevenson, E.F. Walborg, J.E. Klaunig, 1997. Role of oxidative stress in the mechanism of dieldrin's hepatotoxicity. Ann. Clin. Lab. Sci., 27: 196-209.
- Badalov, N., R. Baradarin, I. Kadirawel, K. Iswara, J. Li, W. Steinberg, *et al.*, 2007. Drug-induced acute pancreatitis. An evidence-based review. Clin Gastroenterol Hepatol., 5: 648-661.
- Balani, A.R., J.H. Grendell, 2008. Drug-induced pancreatitis. Incidence, management and prevention. Drug Saf., 31: 823-837.
- Banerjee, P., S.S. Bhattacharyya, N. Bhattacharjee, S. Pathak, N. Boujedaini, P. Belon, A.R. KhudaBukhsh, 2009. Ascorbic acid combats Arsenic-induced oxidative stress in mice liver. Ecotoxicol Environ Safety., 72(2): 639-649.
- Barr, D.B., R. Allen, A.O. Olsson, R. Bravo, L.M. Caltabiano, A. Montesano, J. Nguyen, S. Udunka, D. Walden, R.D. Walker, G. Weerasekera, R.D. Whitehead Jr, S.E. Schober, L.L. Needham, 2005. Concentrations of selective metabolites of organophosphorus pesticides in the United States population, Environ. Res., 99: 314-326.

- Bashir, S., Y. Sharma, M. Irshad, S. Dutta Gupta, T.D. Dogra, 2006. Arsenic-induced cell death in liver and brain of experimental rats. *Basic Clin Pharmacol Toxicol.*, 98(1): 38-43.
- Bates, H.M., 1983. Insulin and *pheochromocytoma*. *Lab. Management*. 21: 11.
- Benbrahim-Tallaa, L., M.P. Waalkes, 2008. Inorganic Arsenic and human prostate cancer. *Environ. Health Perspect.*, 116: 158-164.
- Eaton, D.L., C.D. Klaassen, 2001. Principles of toxicology. In: Klaassen CD (ed) Casarett and Doull's toxicology. The basic science of poisons. McGraw-Hill, New York, pp: 11-34.
- Elhalwagy, M.E.A., N.I. Zaki, 2009. Comparative study on pesticide mixture of organophosphorus and pyrethroid in commercial formulation. *Environ. Toxicol. Pharmacol.*, 28: 219-224.
- Ellman, G.L., D.K. Courtney, V. Andres, Jr., R.M. Featherstone, 1961. A new rapid colorimetric determination of acetylcholinesterase activity. *Biochem Pharmacol.*, 7: 88-95.
- Ferguson, D.V., D.W. Roberts, H. Han-Shu, A. Andrews, R.W. Benson, T.J. Bucci, J.A. Hinson, 1990. Acetaminophen-induced alterations in pancreatic beta cells and serum insulin concentrations in B6C3F1 mice. *Toxicol Appl Pharmacol.*, 15: 104(2): 225-34.
- Fu, J., C.G. Woods, E. Yehuda-Shnaidman, Q. Zhang, V. Wong, S. Collins, G. Sun, M.E. Andersen, J. Pi, 2010. Low-Level Arsenic Impairs Glucose-Stimulated Insulin Secretion in Pancreatic Beta Cells. Involvement of Cellular Adaptive Response to Oxidative Stress. *Environ Health Perspect.*, 118: 864-870. doi:10.1289/ehp.0901608.
- Furlong, C.E., R.J. Richter, S.L. Seidel, L.G. Costa, A.G. Motulsky, 1989. Spectrophotometric assays for the enzymatic hydrolysis of the active metabolites of chlorpyrifos and parathion by plasma paraoxonase. *arylesterase. Anal Biochem.*, 180: 242-7.
- Gokcimen, A., K. Gulle, H. Demirin, D. Bayram, A. Kocak, I. Altuntas, 2007. Effects of diazinon at different doses on rat liver and pancreas tissues. *Pestic. Biochem. Physiol.*, 87: 103-108.
- Groten, J.P., F.R. Cassee, P.J. Van Bladeren, C.De. Rosa, V.J. Feron, 1999. Mixtures, in *Toxicology*. Marguardt, H., Schafer, S.G., McClellan, R., Welsch, F. (eds). Academic Press. NY. pp: 257-270.
- Gupta, J., J. Datta, A. Sarkar, D. Sengupta, 1992. Effect of Malathion on antioxidant defense system in human fetus- an in vitro study. *J. Exp. Biol.*, (30): 352-354.
- Harputluoglu, M.M., B. Kantarceken, M. Karıncaoglu, M. Aladag, R. Yildiz, M. Ates, B. Yildirim, F. Hilmioglu, 2003. Acute pancreatitis. An obscure complication of organophosphate intoxication, *Hum. Exp. Toxicol.*, 22: 341-343.
- Hernández, A.F., F. Gil, E. Leno, O. López, L. Rodrigo, A. Pla, 2009. Interaction between human serum esterases and environmental metal compounds. *Neurotoxicology*, 30: 628-635.
- Hernandez, A.F., M.A. Gomez, G. Pena, *et al.*, 2004. Effect of long term exposure to pesticides on plasma esterases from plastic green house workers. *J Toxicol Environ Health A*. 67: 1095-108.
- Hinson, J.A., H. Han-Hsu, J.B. Mays, S.J. Holt, P. McLean, B. Ketterer, 1984. Acetaminophen-induced alterations in blood glucose and blood insulin levels in mice. *Res Commun Chem Pathol Pharmacol*, 43(3): 381-91.
- Hsiao, C.T., C.C. Yang, J.F. Deng, M.J. Bullard, S.J. Liaw, 1996. Acute pancreatitis following organophosphate intoxication. *J. Toxicol. Clin. Toxicol.*, 34: 343-347.
- Inada, C., K. Yamada, N. Takane, K. Nonaka, 1995. Poly (ADP ribose) synthesis induced by nitric oxide in a mouse beta-cell line. *Life Sci.*, 56: 1467-1474.
- Ita, S.O., E.O. Akpanyung, B.I. Umoh, E.E. Ben, S.O. Ukafia, 2009. Acetaminophen induced hepatic toxicity. Protective role of *Ageratum conyzoides*. *Pak. j. Nutr.*, 8(7): 928-932.
- Izquierdo-Vega, J.A., C.A. Soto, L.C. Sanchez-Pena, A. De Vizcaya-Ruiz, L.M. Del Razo, 2006. Diabetogenic effects and pancreatic oxidative damage in rats subchronically exposed to arsenite. *Toxicol Lett.*, 160(2): 135-142.
- Junge, W., k. Leybold, B. Kraack, 1983. Influence of colipase on the turbidimetric determination of pancreatic lipase catalytic activity. *J. Clin. Chem. Clin. Biochem.*, 21: 445-451.
- Karant, S., J. Liu, N. Mirajkar, C. Pope, 2006. Effects of acute chlorpyrifos exposure on in vivo acetylcholine accumulation in rat striatum. *Toxicol Appl Pharmacol.*, 216(1): 150-156.
- Kim, S.J., M.Y. Lee, Y. Kwondo, S.Y. Kim, Y.C. Kim, 2009. Alteration in metabolism and toxicity of Acetaminophen upon repeated administration in rats. *J Pharmacol Sci.*, 111(2): 175-81.
- Kostopanagiotou, G.G., A.D. Grypioti, P. Matsota, M.G. Mykoniatis, C.A. Demopoulos, Z. Papadopoulos-Daifoti, A. Pandazi, 2009. Acetaminophen-induced liver injury and oxidative stress. Protective effect of propofol. *Eur J Anaesthesiol.*, 26(7): 548-53.
- Lamberta, J.C., L.K. Teuschler, G.E. Ricea, J.M. Wrighta, J.C. Lipscomba, 2011. Cumulative environmental risk. *Encyclopedia of Environmental Health.*, 852-859.
- Lent, R.W., 1986. Determination of amylase enzyme. *CLin. chem.*, 32: 1136.
- Liao, Y.T., W.F. Li, C.J. Chen, R.J. Prineas, W.J. Chen, Z.M. Zhang, C.W. Sun, S.L. Wang, 2009. Synergistic effect of polymorphisms of paraoxonase gene cluster and Arsenic exposure on electrocardiogram abnormality. *Toxicol Appl Pharmacol.*, 239(2): 178-83.
- Manimaran, A., S.N. Sarkar, P. Sankar, 2010a. Influence of repeated preexposure to Arsenic on Acetaminophen-induced oxidative stress in liver of male rats. *Food Chem Toxicol.*, 48(2): 605-10.

- Manimaran, A., S.N. Sarkar, P. Sankar, 2010b. Toxicodynamics of subacute co-exposure to groundwater contaminant Arsenic and analgesic-antipyretic drug Acetaminophen in rats. *Ecotoxicol Environ Saf.*, 73(1): 94-100.
- Mansour, S.A., A.A. Refaie, S.A. Nada, 2001. Xenobiotics interaction.4- Effect of some pesticides and their mixtures on the growth rate of albino rats. *Ad. Pharmacol. Toxicol.*, 2(21): 9-24.
- Mukherjee, S., D. Das, S. Darbar, C. Mitra, 2003. Dietary intervention affects Arsenic-generated nitric oxide and reactive oxygen intermediate toxicity in islet cells of rats. *Curr Sci.*, 85(6): 786-793.
- Mukherjee, S., D. Das, S. Darbar, M. Mukherjee, A.S. Das, C. Mitra, 2004. Arsenic trioxide generates oxidative stress and islet cell toxicity in rabbit. *Curr Sci.*, 86(6): 854- 857.
- Mussa, T.A., A.A. El Asser, M.A. El-Banhawy, 1984. In *Principles and Practice of Histochemistry*. printed and publishing by Dar Al Maarf. Cairo, chapter (V): 187-195.
- National Research Council NRC, 1999. Arsenic in the drinking water. Washington, DC. National Academy Press, pp: 1-310.
- Navas-Acien, A., A.R. Sharrett, E.K. Silbergeld, B.S. Schwartz, K.E. Nachman, T.A. Burke, E. Guallar, 2005. Arsenic exposure and cardiovascular disease. A systematic review of the epidemiologic evidence. *Am. J. Epidemiol.*, 162: 1037-1049.
- Navas-Acien, A., E.K. Silbergeld, R. Pastor-Barriuso, E. Guallar, 2008. Arsenic exposure and prevalence of type 2 Diabetes in US adults. *JAMA*. 300(7): 814-822. (doi.10.1001/jama.300.7.814).
- Navas-Acien, A., E.K. Silbergeld, R.A. Streeter, J.M. Clark, T.A. Burke, E. Guallar, 2006. Arsenic exposure and type 2 Diabetes. a systematic review of the experimental and epidemiological evidence. *Environ Health Perspect.*, 114(5): 641-648.
- Naziroğlu, M., A. CihangirUğuz, A. Koçak, R. Bal, 2009. Acetaminophen at different doses protects brain microsomal Ca²⁺-ATPase and the antioxidant redox system in rats. *J Membr Biol.*, 231(2-3): 57-64.
- Organization for Economic Cooperation and Development OECD., 1992. Chairman's Report of the meeting of the ad hoc working group of experts on systemic short term and (delayed) neurotoxicity.
- Patlolla, A.K., P.B. Tchounwou, 2005. Serum Acetyl Cholinesterase as a Biomarker of Arsenic Induced Neurotoxicity in Sprague-Dawley Rats. *Int. J. Environ. Res. Public Health.*, 2(1): 80-83.
- Paul, D.S., A.W. Harmon, V. Devesa, D.J. Thomas, M. Styblo, 2007. Molecular mechanisms of the diabetogenic effects of Arsenic. Inhibition of insulin signaling by arsenite and methylarsonous acid. *Environ Health Perspect.*, 115(5): 734-742.
- Pournourmohammadi, S., B. Farzami, S.N. Ostad, E. Azizi, M. Abdollahi, 2005. Effects of Malathion subchronic exposure on rat skeletal muscle glucose metabolism. *Environ. Toxicol. Pharmacol.*, (19): 191-196.
- Pournourmohammadi, S., S.N. Ostad, E. Azizi, M.H. Ghahremani, B. Farzami, B. Minaie, B. Larijani, M. Abdollahi, 2007. Induction of insulin resistance by Malathion. Evidence for disrupted islets cells metabolism and mitochondrial dysfunction. *Pesticide Biochem. Physiol.*, 88: 346-352.
- Reitman, S.M.D., S. Frankel, 1957. A colorimetric method for the determination of serum glutamic oxaloacetic and glutamic pyruvic transaminase. *Am. J. Clin. Path.*, 28: 56-63.
- Saad, A., M.A. Hassanien, 2001. Assessment of Arsenic level in the hair of the non occupational Egyptian population. Pilot study. *Environ Int.*, 27(6): 471-478.
- Schalm, O.W., 1986. *Veterinary Hematology*, fourth ed. Lea and Febiger, Philadelphia, pp: 21-36.
- Schmidt, L.E., K. Dalhoff, 2004. Hyperamylasemia and acute pancreatitis in Paracetamol poisoning. *Aliment Pharmacol Ther.*, 20: 173-9.
- Seirafi, M., A. Iten, A. Hadengue, 2007. Acetaminophen. Hepatotoxicity at therapeutic doses and risk factors. *Rev Med Suisse.*, 3(129): 2345-9.
- Siller, F.R., B. Quintanilla-Vega, M.E. Cebrian, A. Albores, 1997. Effects of arsenite pretreatment on the acute toxicity of parathion. *Toxicology*, 116: 59-65.
- Simmons, J.E., 1995. Chemical mixtures. Challenge for toxicology and risk assessment. *Toxicology*, 105 (2-3): 111-119.
- Smedley, P.L., D.G. Kinniburgh, 2002. A review of the source, behavior and distribution of Arsenic in natural waters. *Appl Geochem.*, 17(5): 517-568. doi.10.1016/S0883-2927(02)00018-5.
- Tos-Luty, S., D.O. Przebirowska, J. Latuszinska, R.M. Tokaraska, M.A. Haratym, 2003. Dermal and oral toxicity of Malathion in rats. *Ann. Agric. Environ. Med.*, 10: 101-106.
- Trinder, P., 1959. Determination of blood glucose using 4-aminophenazone. *J. Clin. Pathol.*, 22: 246.
- Waalkes, M.P., L.K. Keefer, B.A. Diwan, 2000. Induction of proliferative lesions of the uterus, testes, and liver in Swiss mice given repeated injections of sodium arsenate. Possible estrogenic mode of action. *Toxicol Appl Pharmacol.*, 166(1): 24-35.
- World Health Organization WHO, 2004. Chemical Fact Sheets, Arsenic. Guidelines for Drinking Water Quality, 3rd ed. Vol 1. Geneva. World Health Organization, 306-308.
- Yanpallewar, S.U., S. Sen, S. Tapas, M. Kumar, S.S. Raju, S.B. Acharya, 2003. Effect of *Azadirachta indica* on Paracetamol-induced hepatic damage in albino rats. *Phytomedicine.*, 10(5): 391-396.
- Yoshikawa, Y., M. Morita, H. Hosomi, K. Tsuneyama, T. Fukami, M. Nakajima, T. Yokoi, 2009. Knockdown of superoxide dismutase 2 enhances Acetaminophen-induced hepatotoxicity in rat. *Toxicology*, (1) 264: 1-2.