

Evaluation of Protective and Antioxidant Activity of Thyme (*Thymus Vulgaris*) Extract on Paracetamol-Induced Toxicity in Rats

¹Monira A. Abd El Kader and ²Naima Z. Mohamed

¹Biochemistry Department, Genetic Engineering and Biotechnology Division.

²Therapeutic Chemistry, Department National Research Center, Dokki, Cairo, Egypt

Abstract: Paracetamol is a common analgesic and antipyretic drug which is safe in therapeutic doses but can produce life-threatening hepatic and renal damages with toxic doses. The current study was designed to investigate the protective effects of aqueous extract of thyme (*Thymus Vulgaris*) against paracetamol-induced toxicity in male albino rats. A total of 24 rats were used for the study. The rats were grouped into four with sex rats in each group. Group I was the control, group II received thyme extract at a dose of 500 mg / kg body weight for 14 days. group III received paracetamol at a dose of 200 mg / kg body weight / ml without extract for 14 days, and group IV received paracetamol plus thyme extract for 14 days. Administration of paracetamol to rats induced marked disturbance of hepatic and renal functions, characterized by a significant increase in the levels of aspartate aminotransferase (AST), alanine aminotransferase (ALT), alkaline phosphatase (ALP), total bilirubin, total protein, blood urea and serum creatinine ($p < 0.01$) and injured the hepatic and renal cells evident from increased level of malondialdehyde (MDA) ($p < 0.01$) along with depletion of super oxide dismutase (SOD), catalase (CAT), activities and reduced glutathione (GSH) levels ($p < 0.01$). Histopathological changes showed that paracetamol caused significant structural damages to liver and kidneys. Oral co-administration of thyme extract with paracetamol significantly decreased the level of liver enzymes (ALT, AST and ALP), total bilirubin, total protein, blood urea and creatinine. The increased levels of lipid peroxidation in tissues were reverted significantly. Thyme treatment also resulted in a significant increase in CAT, SOD and GSH in both liver and kidneys. Moreover, thyme extract also exhibited some improvement in the histological architecture of liver and kidney. These results clearly show the antioxidant and protective property of thyme extract.

Key words: Paracetamol, thyme, antioxidants, hepatotoxicity, nephrotoxicity, rats.

INTRODUCTION

The liver plays a central role in transforming and clearing chemicals and is susceptible to the toxicity from these agents. Certain medicinal agents, when taken in overdoses and sometimes even when introduced within therapeutic ranges, may injure the organ. Drugs are an important cause of liver injury. More than 900 drugs, toxins, and herbs have been reported to cause liver injury (Friedman *et al.*, 2003) and it is the most common reason for a drug to be withdrawn from the market. Drugs are also, a common source of acute renal injury and cause approximately 20 percent of community- and hospital- acquired episodes of acute renal failure (Bellomo, 2006). Renal toxicity should not be confused with the fact that some medications have a predominantly renal excretion and need their dose adjusted for the decreased renal function.

Paracetamol is a common analgesic and antipyretic drug which is safe in therapeutic doses but can produce life-threatening hepatic and renal damages in man, rats and mice with toxic doses (Roberts *et al.*, 2001; Abraham, 2005). Protection against paracetamol – induced hepatorenal-toxicity has been used as a test for potential protective activity by several investigators (Visen *et al.*, 1993).

A number of drugs or chemicals such as melatonin, vitamin E and N-acetyl-cysteine have been used to prevent paracetamol -induced hepatic and renal injury (Sener *et al.*, 2003). Increased use of synthetic drug therapy leads to many side effects and undesirable hazards. Therefore there is a worldwide trend to return to natural resources, which are culturally acceptable and economically viable. Thyme (*Thymus vulgaris L.*) belongs to the Lamiaceae family and aromatic native herbs in the Mediterranean region. It is now widely cultivated as tea, spice and herbal medicine (Ozguven and Tansi, 1998; Domaracky *et al.*, 2007). The leafy parts of thyme and its essential oil have been used in foods for the flavour, aroma and preservation so added to meat, fish and food products. Thyme has changed from a traditional herb to a serious drug in rational phytotherapy. Thyme possess various beneficial effects, e.g., antiseptic, antimicrobial, bactericidal, anthelmintic, antioxidant properties and it has recently suggested as a natural replacement for synthetic antioxidant (Rasooli *et al.*, 2006). Thyme is an excellent source of iron, manganese and vitamin K. It is also a very good source of calcium (Sasaki *et al.*, 2005). Moreover, thyme, promotes blood circulation and functions as an exciting stimulant for the entire system. The

Corresponding Authors: Monira A. Abd El Kader, Biochemistry Department, Genetic Engineering and Biotechnology Division.

E-mail: mkader1233@yahoo.com

stimulating action on the nervous system makes the herb a brilliant remedy for physical as well as mental fatigue, alleviating tension, anxiety and sleeplessness. The herb is also effective in treating depression or mood changes (Höferl *et al.*, 2006).

The therapeutic potential of thyme rests on its contents of flavonoids, thymol, carvacrol, eugenol, aliphatic phenols as well as saponins, luteolin and tetramethoxylated flavones.(Dorman and Deans,2000 ; Amarowicz *et al.*, 2008). The present study was designed to assess whether the toxic effects caused by administration of paracetamol could be prevented or ameliorated by treatment with thyme extract.

MATERIALS AND METHODS

Chemicals:

Reagent kits for assay of AST, ALT, ALP, total bilirubin, total protein, urea and creatinine, were purchased from Quimica Clinica Aplicada S.A (Spain). Reagent kits for determination of malondialdehyde (MDA), reduced glutathione (GSH) catalase (CAT) and superoxide dismutase (SOD) were purchased from Biodiagnostics (Egypt). All other chemicals and solvents used in this study were of highest purity and analytical grade, and purchased from Sigma-Aldrich chemic (Deisenhofen, Germany).

Plant Material and Extraction Procedure:

Dried leaves of thyme (*Thymus vulgaris*) were purchased from local market in Giza, Egypt. The leaves of thyme were grounded into powder using a grinder. One hundred g of fine-powder were subjected to extraction with 200 ml boiling distilled water in covered flask until complete exhaustion and left for 30 min. Thereafter, the extract was cooled and filtered using Whatman No.1 filter paper to remove particulate matter (Kandil *et al.*, 1994). The filtrate was dried using freeze dried system (Dum-Dry Freeze Dryer, Model PAC-TC -V4, FTS system, Inc., Stone Ridge ,NY,USA).The required doses were taken and reconstituted in 10 ml of distilled water just before oral administration.

Animals:

Twenty four adult male Sprague-Dawley rats weighing about 120-150 g, were obtained from The Animal House of National Research Centre. All animals were housed in plastic cages and kept under the same laboratory conditions of temperature (25±2°C) and lighting (12:12hr light: dark cycle), for one week prior to starting the experiments. The rats were provided *ad libitum* with tap water and fed with standard commercial rat chow. Animal procedures were performed in accordance with Guidelines for Ethical Conduct in the Care and Use of Animals.

Experimental Design:

The animals were divided randomly into four groups of sex rats each. Paracetamol was prepared in distilled water and administered orally at the dose of 200 mg/kg body wt. (Vidhya Malar and Mary Mettilda Bai, 2009), while the thyme extract was administered by oral gavage at a dose of 500 mg/kg body wt. (Shati and Elsaid, 2009).

Group I: Vehicle (distilled water) treated rats were received daily dose of distilled water for 14 days and served as control.

Group II: Rats received thyme extract (500 mg/kg b. wt /day, orally) for 14 days.

Group III: Rats received paracetamol (200 mg/kg b. wt /day, orally) for 14 days.

Group IV: Rats received paracetamol as in group III and after 30 min thyme extract was administered as in group II for 14 days.

Biochemical Analysis:

At the end of the experimental period, the animals were fasted for 16-18 hrs. before sacrificing. The animals of all groups were sacrificed and the blood sample of each animal was collected separately by carotid bleeding into sterilized tubes for separation of serum for different biochemical analysis like AST, ALT (Reitman and Frankel, 1957), ALP (Babson *et al.*, 1966), total bilirubin (Schmidt and Eisenburg, 1975), total protein (Henery, 1964), creatinine (Schirmeister *et al.*, 1964) and urea (Foster and Hocholzer, 1971). Portions of liver and kidneys were immediately washed in ice cold physiological saline and homogenized in 50mM potassium phosphate (pH 7.4) to render 10% homogenate. The homogenate was centrifuged at 4000 rpm for 15 min. at 4°C. The supernatant was used for MDA (Ohkawa, *et al.*, 1979), GSH (Beutler *et al.*, 1963), SOD (Nishikimi *et al.*, 1972), and CAT (Aebi, 1984) analysis.

Histological Investigation:

Small portions of liver and kidneys were preserved in 10% neutral buffered formalin, embedded in paraffin wax and sectioned at 5µm. The sections were stained with haematoxyline and eosin for histological examination (Ross *et al*, 1989).

Statistical Analysis:

The results were expressed as mean ± SE of studied groups using the analysis of variance test (one way ANOVA) followed by Bonferroni test. All analysis were performed by statistical package for the social science software (SPSS Inc., Chicago, IL). Values of P<0.05 were considered significant.

Results:

The extent of paracetamol induced hepatotoxic effect was assessed by the level of released cytoplasmic enzymes such as ALT ,AST and ALP in circulation. The activities of tranaminases and ALP and the level of total bilirubin and total protein are shown in Table1. The level of ALT, AST, ALP and total bilirubin increased significantly (P<0.01) in paracetamol –treated rats (Group III), while the content of total protein decreased (P<0.01) significantly when compared with control (Group I). Co-treatment with thyme extract and paracetamol (Group IV) reduced the concentration of ALT, AST, ALP and total bilirubin while increasing total protein content significantly (P<0.01).

Indices of kidney functions were displayed in Table 2. The levels of urea and creatinine significantly (P<0.01) increased in serum of rats received paracetamol as compared to control group. On the other hand, rats administered thyme extract alone(Group II) revealed a non-significant change in the mentioned parameters as compared to control group. The co-treatment with thyme extract recorded significant decrement in urea (P<0.01) and creatinine (P<0.05) in comparison with paracetamol –treated group.

Table 3 shows the effects of the administration of thyme extract on the levels of liver MDA and GSH and the activities of SOD and CAT in paracetamol-treated rats. Paracetamol treatment brought about a significant (P<0.01) depletion of SOD,CAT and GSH with increased (P<0.01) MDA levels. Co-treatment with thyme extract (Group IV) significantly (P<0.05) elevated the activity of both CAT and SOD as well as GSH content (P<0.01) with marked decrease in the MDA level in hepatic tissue when compared with paracetamol –treated rat. Treatment with thyme extract alone significantly (P<0.05) increased hepatic GSH content as compared with control group.

Administration of paracetamol caused a significant (P<0.01) elevation in MDA level in kidney homogenate as compared with control group. Co-treatment with thyme extract induced significant (P<0.05) decrease in MDA level when compared with paracetamol treated group (Table4). Also treatment with paracetamol led to a significant decrement (P<0.01) in SOD and CAT activities and GSH content in renal tissue as compared to control group. However, co-administration with thyme extract improved the reduction of CAT and SOD activities and GSH content (P<0.05) that induced by paracetamol. The treatment with thyme extract alone significantly(P<0.05) increased GSH content when compared with control rats.

Table 1: Effect of administration of paracetamol alone or with thyme extract on serum liver functions.

Group	Treatment	AST (U/ml)	ALT (U/ml)	ALP (U/ml)	Total Bilirubin (mg/dL)	Total Protein (g/dL)
Group I	Control	37.96 ± 1.88	21.71 ± 0.62	89.23 ± 4.45	0.61 ± 0.02	8.40 ± 0.90
Group II	Thyme Extract	39.80 ± 1.70	23.61 ± 0.57	90.34 ± 4.52	0.63 ± 0.03	7.9 ± 0.3
Group III	Paracetamol	123.60** ^a ± 1.94	104.93** ^a ± 1.83	200.57** ^a ± 3.46	5.40** ^a ± 0.31	3.7** ^a ± 0.4
Group IV	Paracetamol +Thyme Extract	50.11** ^b ± 1.07	47.64** ^b ± 1.75	112.41** ^b ± 0.55	0.93** ^b ± 0.01	6.9** ^b ± 0.7

Values are expressed as mean ± SE (n=6) , a: Group III was compared to the Group I, b: Group IV was compared to Group III.* significant at P<0.05, **significant at P<0.01.

Table 2: Effect of administration of paracetamol alone or with thyme extract on serum kidney functions.

Group	Treatment	Urea (mg/dL)	Creatinine (mg/dL)
Group I	Control	19.6 ± 2.1	0.24 ± 0.04
Group II	Thyme Extract	21.3 ± 1.4	0.22 ± 0.01
Group III	Paracetamol	80.1 ± 8.2** ^a	1.24 ± 0.43** ^a
Group IV	Paracetamol+ Thyme xtract	38.1 ± 3.7** ^b	0.84 ± 0.07** ^b

Values are expressed as mean ± SE (n=6) , a: Group III was compared to the Group I, b: Group IV was compared to Group III.* significant at P<0.05, **significant at P< 0.01.

Table 3: Effect of administration of paracetamol alone or with thyme extract on markers of oxidative stress in liver tissues.

Group	Treatment	MDA nmol/g tissue	SOD U/g tissue	CAT U/g tissue	GSH µg /g tissue
Group I	Control	28.71 ±2.01	441.74 ±26.42	1.64 ±0.05	1.20 ± 0.10
Group II	Thyme Extract	26.96 ±2.15	434.11 ±30.90	1.73 ±0.07	1.98 ± 0.20 ^a
Group III	Paracetamol	98.73 ±3.86 ^{**a}	226.76 ±23.39 ^{**a}	0.80 ±0.07 ^{**a}	0.79 ± 0.08 ^{**a}
Group IV	Paracetamol+ Thyme Extract	51.23 ±5.07 ^{**b}	296.23 ±26.12 ^b	1.09 ±0.07 ^b	1.13 ± 0.16 ^{**b}

Values are expressed as mean ± SE (n=6) , a: Group II and Group III were compared to the Group I, b: Group IV was compared to Group III.* significant at P<0.05, **significant at p<0.01

Table 4: Effect of administration of paracetamol alone or with thyme extract on markers of oxidative stress in kidney tissues.

Group	Treatment	MDA nmol/g tissue	SOD U/g tissue	CAT U/g tissue	GSH µg/g tissue
Group I	Control	35.3 ± 5.9	389.82 ±20.13	1.99 ±0.11	1.9 ± 0.2
Group II	Thyme Extract	37.1 ± 3.6	390.38 ±24.60	2.69 ±0.27	2.5 ± 0.2 ^a
Group III	Paracetamol	79.4 ± 4.9 ^{**a}	231.16 ±20.71 ^{**a}	0.79 ±0.06 ^{**a}	0.96 ± 0.1 ^{**a}
Group IV	Paracetamol+ Thyme Extract	41.8 ± 4.9 ^{*b}	310.26 ±29.71 ^b	1.16 ±0.10 ^b	1.7 ± 0.5 ^b

Values are expressed as mean ± SE (n=6) , a: Group II and Group III were compared to the Group I, b: Group IV was compared to Group III.* significant at P<0.05, **significant at p<0.01.

In the histopathological studies, the liver sections of rats treated with vehicle showed normal hepatic architecture with polyhedral hepatocytes , rounded vesicular nuclei and eosinophilic cytoplasm (Fig.1-a). In rats treated with thyme extract alone, a normal hepatic architecture were observed (Fig. 1-b). The histoarchitecture of paracetamol- treated rat liver showed cloudy swelling , degeneration of hepatocytes and lymphocytic infiltration (Fig. 1-c). In the group of animals administered thyme extract with paracetamol showed protective effects in the liver where slight degenerative changes were observed (Fig. 1-d).

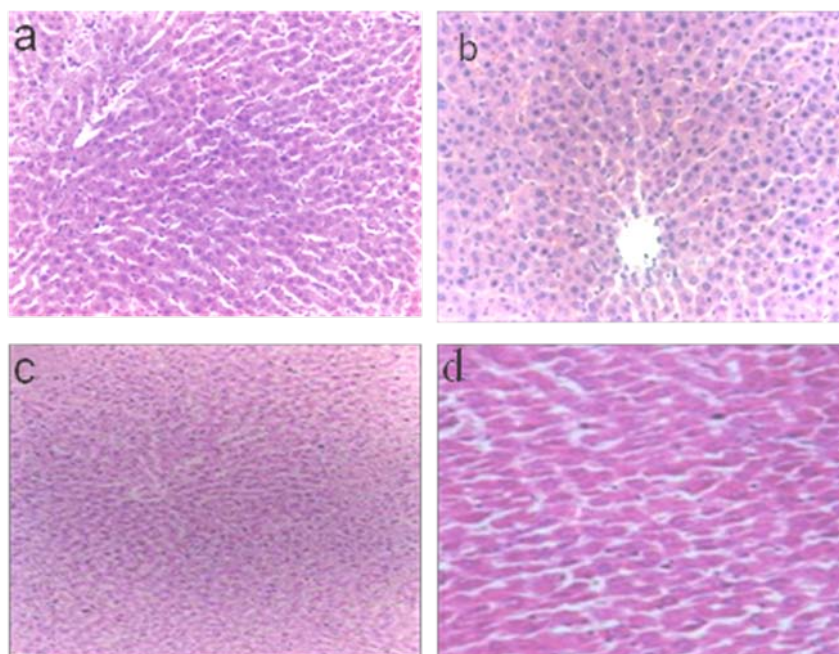


Fig. 1: A photomicrographs of liver sections showing effect of various treatments: (a) Liver of control rat showing normal architecture of hepatocytes (H and E, X100); (b) Liver of rat treated with thyme extract alone showing almost normal histology of hepatic tissue (H and E, X40). (c) Liver section of paracetamol –treated rats, demonstrating cloudy swelling ; hepatocytes degeneration and lymphocytic infiltration (H and E, X40); (d) Liver section of rat treated with paracetamol and thyme extract showing slight degenerative changes (H and E, X40).

Histological study for the kidneys of the control rats revealed normal glomerulus surrounded by the Bowman's capsule, proximal and distal convoluted tubules without any inflammatory changes (Fig. 2-a). The normal structure in most of proximal and distal tubules and renal corpuscle with slight changes in renal tissue appeared in thyme extract-treated rats (Fig. 2-b). The treatment with paracetamol induced marked alterations in renal tissues (Fig. 2-c) when compared to the control group. These changes were in the form of acute tubular necrosis and the congestion of the glomerular epithelium with massive vacuolization in the cytoplasm. Treatment with paracetamol and thyme extract showing marked improvement in most proximal and distal tubules and glomeruli (Fig. 2-d).

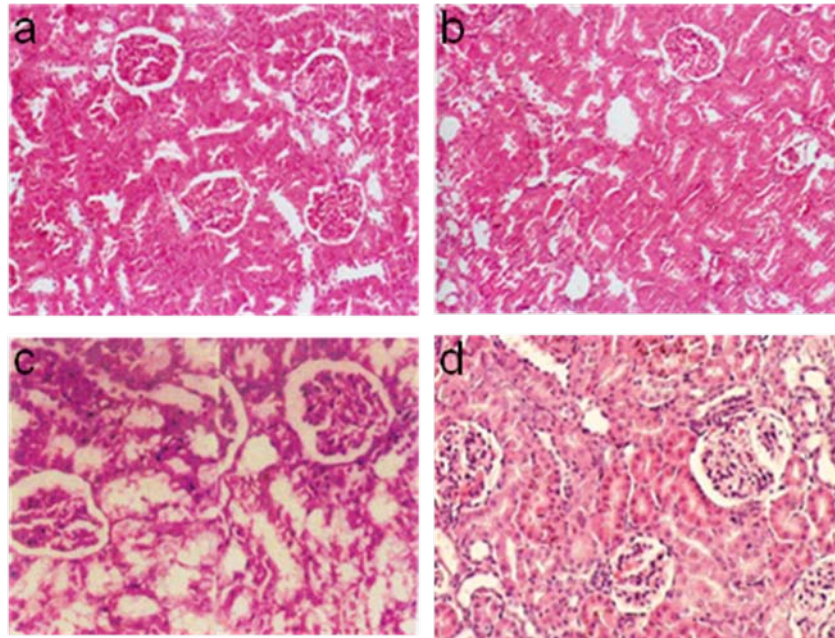


Fig. 2: A photomicrographs of kidney sections showing effect of various treatments: (a) control rats showing the normal structure of proximal tubules and normal glomerular capsule with urinary space, (b) thyme extract-treated rats showing the normal structure in most of proximal and distal tubules and renal corpuscle (H&E, X100), (c) paracetamol-treated rats showing acute tubular necrosis and the congestion of the glomerular epithelium with massive vacuolization in the cytoplasm (H & E, X225) and (d) rats co-treated with paracetamol and thyme extract showing marked improvement in most proximal and distal tubules and glomeruli (H&E, X125).

Discussion:

Acute large doses or chronic use of paracetamol is commonly associated with hepatotoxicity and nephrotoxicity in humans as well as animals (Schnellman, 2001). The present study confirmed that the paracetamol, in over dosage, was found to cause liver injury which clinically manifested as jaundice, steatosis and fibrosis (Lewis *et al.*, 2006). Our results demonstrated increase in AST and ALT activities as released into systemic circulation due to membrane damage of hepatocytes and necrosis. Paracetamol intoxication also facilitates the release of ALP due to hepato-biliary damage. In the current study, the elevated serum level of ALP might be due to increase synthesis in presence of increasing biliary pressure as described by Prakash *et al.* (2001). In addition, our results reported increased level of serum bilirubin, thereby suggesting severe hepatic injury and confirming the hepatotoxic nature of paracetamol. Serum bilirubin is considered as an index for the assessment of hepatic function and any abnormal increase indicates hepatobiliary disease and severe disturbance of hepatocellular architecture (Martin and Friedman, 1992). Moreover, hepatotoxin impairs the capacity of liver to synthesize albumin (Dubey *et al.*, 1994). In the current study, decreased total serum protein level in paracetamol treated rats may be attributed to impaired protein synthesis by damaged liver tissue.

In the present study, the elevations in the levels of MDA - the end products of lipid peroxidation- in the liver of rat treated with paracetamol suggests tissue damage and failure of antioxidant defense mechanisms as evidenced by decreased activities of protective enzymes such as SOD and CAT activities and GSH content in liver tissue after paracetamol administration. An explanation for the depletion of GSH content in hepatic tissue has been described previously. Paracetamol in larger doses produces liver necrosis after undergoing bio-activation to a toxic electrophile, N-acetyl-p-benzoquinoneimine (NAPQI) by cytochrome P-450 monooxygenase. NAPQI, in turn, is detoxified by conjugating with GSH leading to its depletion (Lee *et al.*, 1996). Thus, GSH constitute the first line of defense against paracetamol -induced generation of free radicals (James. *et*

al., 2003). NAPQI binds to macromolecules and cellular proteins, and also oxidizes lipids and alters homeostasis of calcium after depletion of SOD, CAT and GSH .

The histological results reported in the current study confirmed the biochemical results and indicated that paracetamol induced damages to hepatic tissues. Similar histological changes in the liver have been demonstrated previously (Vidhya Malar and Mary Mettilda Bai , 2009; Al- Sowyan,2009).

In the present study, paracetamol -induced nephrotoxicity was characterized by marked elevations in blood urea and serum creatinine. Our findings were in accordance with that reported by Abubaker Siddiq *et al.*(2012). It has suggested that in nephrotoxicity and renal diseases, the serum urea and creatinine accumulates because the rate of production exceeds the rate of clearance due to the defect in renal function (Mayne,1994). Paracetamol nephrotoxicity occurs due to its highly reactive metabolite- NAPQI- which arylates proteins in the proximal tubule, initiating cell death of renal tubular cells (Mugford and Tarloff,1997). Drug-induced nephrotoxicities are often accompanied with marked elevations in blood urea and serum creatinine and acute tubular necrosis and depletion of antioxidant enzyme (Verpooten *et al.*,1998). Furthermore, hepatically derived glutathione conjugates are involved in paracetamol induced renal injury. The kidneys are involved in the excretion of various xenobiotics, pollutants, toxins and hence they are prone to liberate high quantities of free radicals which contribute to high oxidative stress. This is involved in the pathogenesis of kidney damage (Trumper *et al.*,1996).

The present study demonstrated that paracetamol overdose resulted in an increase in the renal MDA level paralleled with the decrease in the SOD and CAT activities as well as GSH level when compared with control rats. Our results were in agreement with that reported by Cohen *et al.*(1998) who concluded that paracetamol -induced oxidative stress results in lipid peroxidation, protein thiols oxidation, depletion of antioxidant enzyme and mitochondrial endoplasmic reticulum injury. Linares *et al.*(2006) suggested that , during renal injury and inflammation, superoxide and peroxide radicals are generated at the site of damage, resulting in the depletion of SOD and CAT activities which are considered the most important enzymes involved in ameliorating the effects of oxygen metabolism.

The biochemical results were also confirmed by the histological findings in the renal tissue which showed acute tubular necrosis and congestion of the glomerular epithelium with massive vacuolization in the cytoplasm. These changes are similar to that reported by Abraham (2005) who demonstrated renal histological alterations following the administration of paracetamol in an overdose.

There have been great efforts to find safe and potent natural antioxidants from various plant sources. Phenolic phytochemicals are thought to promote optimal health through their antioxidant and free radicals scavenging effects (El-Nekeety *et al.*,2011). Aqueous extract of thyme are rich in the total phenolic content and have radical scavenging activity (Hamzawy *et al.*,2012)

Treatment of paracetamol intoxicated rats with thyme extract in the present study, markedly reduced the elevated levels of transaminases, ALP and total bilirubin in serum towards normal indicating its hepatoprotective efficacy and demonstrated membrane stabilizing activity of thyme extract. Also, thyme extract prevented the decrease in the total serum protein level. This further signifies the curative nature of extract against paracetamol toxicity. Moreover, co-administration of thyme alleviates the harmful effects induced by paracetamol by improvement the kidney functions.

Additionally, the current study reported that the administration of thyme extract with paracetamol decreased the levels of MDA and exhibited a marked increase in the activity of SOD and CAT as well as the level of GSH in both hepatic and renal tissue as compared to paracetamol group. This observed increase suggests that the thyme have an efficient protective mechanism in response to reactive oxygen species and may be associated with decreased oxidative stress and free radical-mediated tissue damage because it scavenges the free radicals and this scavenging is one of the major antioxidant mechanisms to inhibit the chain reaction of lipid peroxidation (Seung *et al.*,2005). It is possible for the thyme extract to be mediated its antioxidant activities by enhancing the antioxidant defense enzymes SOD, CAT and replenishing GSH storage. Our data reported increase in the level of GSH in both hepatic and renal tissues of rats treated with thyme alone which may be an evidence for enhancing the antioxidant defense system with thyme. However, the hepatorenoprotective potential of thyme was previously described in alfatoxines- induced liver damage (Hamzawy *et al.*,2012).

The protective property of the extract is further confirmed by significant improvement of the liver and kidney architecture .Thyme alone produced slight changes in renal tissue which may be disappeared by decreasing the used dose of the extract.

In conclusions, the present study suggests that the aqueous thyme extract has a tremendous potential to prevent or reverse the changes induced by paracetamol toxicity back to normal via its antioxidant activity . Hence it is advised that, during treatment with paracetamol in overdose , it is preferable to consume thyme leaves extract as a protective agent.

ACKNOWLEDGMENT

The authors are grateful to the members of histology unit at Research Institute of Ophthalmology, Giza to their help to perform the histological part of the paper.

REFERENCES

- Abraham, P., 2005. Vitamin C may be beneficial in the prevention of paracetamol-induced renal damage. *Clin. Exp. Nephrol.*, 9: 24-30.
- Abubaker Siddiq, I. Shanmukha, S.V. Rajendra and S. Ramachandra Setty, 2012. Protective Effect of *Spathodea Campanulata* Bark against Paracetamol Induced Nephrotoxicity in Rats. *Intern. J. Pharm. Tech. Res.*, 4: 398-403.
- Aebi, H., 1984. Catalase *in vitro*. *Methods Enzymol.*, 5: 121-126.
- Al-Sowyan, N.S., 2009. Efficacy and safety of folic acid during toxic hepatitis induced by acute overdose of paracetamol. *Intern. J. Pharmacol.*, 5: 208-214.
- Amarowicz, R., Z. Zegarska, R. Rafałowski, R.B. Pegg, M. Karamac and A. Kosin, 2008. Antioxidant activity and free radical-scavenging capacity of ethanolic extracts of thyme, oregano, and marjoram. *Eur. J. Lipid Sci. Technol.*, 110: 1-7.
- Babson, L.A, S.J. Greeley, C.M. Coleman and G.D. Philips, 1966. Serum alkaline phosphatase determination. *Clin. Chem.*, 12: 482-490.
- Bellomo, R., 2006. The epidemiology of acute renal failure: 1975 versus 2005. *Curr. Opin. Crit. Care.*, 12: 557-560.
- Beutler, E., O. Duron and B. Kelly, 1963. Improved method for the determination of blood glutathione. *J. Lab. Clin. Med.*, 61: 882-88.
- Cohen, S.D., D.J. Hoivik and E.A. Khairallah, 1998. Acetaminophen-induced hepatotoxicity, In: Plaa, G.L. and W.R. Hewitt eds, *Toxicology of the Liver*, Taylor & Francis, Philadelphia, pp: 159-186.
- Domaracky, M., P. Rehak, S. Juhas and J. Koppel, 2007. Effects of selected plant essential oils on the growth and development of mouse preimplantation embryos *in vivo*. *Physiol. Res.*, 56: 97-104.
- Dorman, H.G.D. and S.G. Deans, 2000. Antimicrobial Plants: Antibacterial Activity of Plant. *Appl. Microbiol.*, 88: 308-316.
- Dubey, G.P., A. Agrawal and S.P. Dixit, 1994. Effect of Liv-52 on different biochemical parameters in alcoholic cirrhosis. *Antiseptic.*, 91: 205-208.
- El-Nekeety, A.A., S.R. Mohamed, A.S. Hathout, N.S. Hassan, S.E. Aly and M.A. Abdel-Wahhab, 2011. Antioxidant properties of *Thymus vulgaris* oil against aflatoxin-induced oxidative stress in male rats. *Toxicol.*, 57: 984-991.
- Foster, L.B. and J.M. Hocholzer, 1971. A single reagent manual method for directly determining urea nitrogen in serum. *Clinical Chemistry*, 17: 921-925.
- Friedman, S.E., J.H. Grendell and K.R. McQuaid, 2003. *Current diagnosis & treatment in gastroenterology*, Lang Medical Books/McGraw-Hill, New York, pp: 664-679.
- Hamzawy, M.A., E.S.M. El-Denshary, N.S. Hassan, F. Manaa and M.A. Abdel-Wahhab, 2012. Antioxidant and hepatoprotective effects of *Thymus vulgaris* extract in rats during aflatoxicosis. *Global J. Pharmacol.*, 6: 106-117.
- Henry, R.J., 1964. Colorimetric determination of total protein. In: *Clinical Chemistry*. Harper and Row Publ., New York, USA, pp: 181.
- Höferl, M., S. Krist and G. Buchbauer, 2006. Chirality influences the effects of linalool on physiological parameters of stress. *Planta Med.*, 72: 1188-1192.
- James, L.P., P.R. Mayeux and J.A. Hinson, 2003. Acetaminophen-induced hepatotoxicity. *Drug Metabolism and Disposition*, 31: 1499-1506.
- Kandil, O., N.M. Radwan, A.B. Hassan, A.M. Amer, H.A. El-Banna and W.M. Amer, 1994. Extracts and fractions of *Thymus capitatus* exhibit antimicrobial activities. *J. Ethnopharmacol.*, 44: 19-24.
- Lee, S.S.T., J.T.M. Buters, T. Pineau, P. Fernandez-Salguero and F.J. Gonzales, 1996. Role of CYP2E1 in hepatotoxicity of acetaminophen. *J. Biol. Chem.*, 271: 12063-12067.
- Lewis, J.H., M. Ahmed, A. Shobassy and C. Palese, 2006. Drug-induced liver disease. *Curr. Opin. Gastroenterol.*, 22: 223-233.
- Linares, M.V., M. Bellés, M.L. Albina, J.J. Sirvent and D.J. Sanchez, 2006. Assessment of the pro-oxidant activity of uranium in kidney and testis of rats. *Toxicol. Lett.*, 167: 52-61.
- Martin, P. and L.S. Friedman, 1992. Assessment of liver function and diagnostic studies. In: Friedman, L.S and E.B. Keefe (Eds.), *Hand Book of Liver Disease*. Churchill Livingstone, Philadelphia, pp: 1-14.
- Mayne, P.D., 1994. The kidneys and renal calculi. In: *Clinical chemistry in diagnosis and treatment*, 6th ed. Edward Arnold Publications, London, pp: 2-24.

- Mugford, C.A. and J.B. Tarloff, 1997. The contribution of oxidation and deacetylation to acetaminophen nephrotoxicity in female Sprague-Dawley rats. *Toxicol. Lett.*, 93: 15-28.
- Nishikimi, M., N.A. Roa and K. Yogi, 1972. Measurement of superoxide dismutase. *Biochem. Biophys. Res. Commun.*, 46: 849-854.
- Ohkawa, H., W. Ohishi and K. Yagi, 1979. Assay for lipid peroxides in animal tissues by thiobarbituric acid reaction. *Anal. Biochem.*, 95: 351.
- Ozguven, M. and S. Tansi, 1998. Drug yield and essential oil of *Thymus vulgaris* L. as influenced by ecological and ontogenetical variation. *Tr. J. of Agriculture and Forestry*, 22: 537-542.
- Prakash, J., S.K. Gupta, V. Kochupillai, N. Singh, Y.K. Gupta and S. Joshi, 2001. Chemopreventive activity of *Withania somnifera* in experimentally induced fibrosarcoma tumors in swiss albino mice. *Phytother. Res.*, 15: 240-244.
- Rasooli, I., M.B. Rezaei and A. Allameh, 2006. Ultra structural studies on antimicrobial efficacy of thyme essential oils on *Listeria monocytogenes*. *International Journal Infectious Diseases*, 10: 236-241.
- Reitman, A. and S.A. Frankel, 1957. Colorimetric method for determination of serum glutamic oxaloacetic and glutamic pyruvic transaminases. *Am. J. Clin. Path.*, 28: 56-63.
- Roberts, L.J., J.D. Marrow, J.G. Hardman and L.E. Limbird, 2001. Analgesic antipyretic and anti-inflammatory agents and drugs employed in the treatment of Gout In: "Goodman and Gilman's" the Pharmacological basis of therapeutics. 10th ed., Hardman J.G. and L.E. Limbird (Eds) ,McGraw Hill, New York, pp: 687-731.
- Ross, M.H., E.J. Reith and L.J. Romrell, 1989. *Histology: A Text and Atlas* (2nd ed). Baltimore. Williams & Wilkins, pp: 51-84.
- Sasaki, K., K. Wada, Y. Tanaka, T. Yoshimura and K. Matuoka, 2005. Thyme (*Thymus Vulgaris* L.) Leaves and its constituents increase the activities of xenobiotic-metabolizing enzyme in mouse liver. *J. Med. Food*, 8: 184-189.
- Schirmeister, J., H. Willmann and H. Kiefer, 1964. Critical evaluation of plasma creatinine as a test of glomerulus filtrate. *Verh Dtsch Ges Inn Med.*, 70: 678-681.
- Schmidt, M. and J. Eisenburg, 1975. Serum bilirubin determination in newborn infants. A new micromethod for the determination of serum of plasma bilirubin in newborn infants. *Fortschr Med.*, 93: 1461-1466.
- Schnellman, R.G., 2001. Toxic responses of the kidney. In: Casarett and Doull's Toxicology: The Basic Science of Poisons, McGraw-Hill Medical Publishing Division, New York, pp: 491-514.
- Sener, G., A. Sehirli and G. Ayanog˘lu-D˘ulger, 2003. Protective effects of melatonin, vitamin E and N-acetylcysteine against acetaminophen toxicity in mice. A comparative study. *J. Pineal. Res.*, 35: 61-68.
- Seung, L., U. Katumi, S. Takayki and L. Kwang-Geum, 2005. Identification of volatile components in basil and thyme leaves and their antioxidants properties. *Food. Chem.*, 91: 131-137.
- Shati, A.A. and F.G. Elsaid, 2009. Effects of water extracts of thyme (*Thymus vulgaris*) and ginger (*Zingiber officinale Roscoe*) on alcohol abuse. *Food Chem. Toxicol.*, 47: 1945-1949.
- Trumper, L., L.A. Monasterolo and M.M. Elias, 1996. Nephrotoxicity of acetaminophen in male Wistar rats: role of hepatically derived metabolites. *J. Pharmacol. Exp. Ther.*, 27: 548-554.
- Verpooten, G.A., P.M. Talkens and W.M. Bennett, 1998. Aminoglycosides and vancomycin. In: De Broe M.E., G.A. Porter, A.M. Bennett and G.A. Verpooten (Eds). *Clinical nephrotoxicants, renal Injury from drugs and chemicals*, Kluwer, The Netherlands, pp: 105-120.
- Vidhya Malar, H.L. and S. Mary Mettilda Bai, 2009. Hepato-protective activity of *Phyllanthus emblica* against paracetamol induced hepatic damage in wister albino rats. *African Journal of Basic & Applied Sciences*, 1: 21-25.
- Visen, P.K.S., B. Shukla, G.K. Patnaik and B.N. Dhawan, 1993. Andrographolide protects rat hepatocytes against paracetamol –induced damage. *J. Ethnopharmacol.*, 40: 11-136.