



AUSTRALIAN JOURNAL OF BASIC AND APPLIED SCIENCES

ISSN:1991-8178 EISSN: 2309-8414
Journal home page: www.ajbasweb.com



Anti-Carcinogenic Effect of Bio-Propolis on Chemically Induced Tongue Cancer in Albino Rats

¹Lawahez El. M. Ismail, ²Nevien M. Ahmed, ³Heba A. Shawky

¹Professor of Oral Pathology, Oral Pathology Department, Faculty of Dentistry, Mansoura University, Egypt.

²Lecturer of Biochemistry, Biochemistry Department, Faculty of Dentistry, Pharos University in Alexandria, Egypt.

³Lecturer of Oral Medicine and Periodontology, Oral Medicine and Periodontics Department, Faculty of Dentistry, Pharos University in Alexandria, Egypt.

Address For Correspondence:

Heba A. Shawky, Lecturer of Oral Medicine and Periodontology, Oral Medicine and Periodontics Department, Faculty of Dentistry, Pharos University in Alexandria, Egypt.
E-mail: shawky_heba@yahoo.com

ARTICLE INFO

Article history:

Received 12 February 2016

Accepted 29 March 2016

Available online 4 April 2016

Keywords:

dysplasia, inflammatory mediators, oxidative enzymes, propolis, squamous cell carcinoma, survivin

ABSTRACT

Background: Cancer of the oral cavity is one of the most common causes of mortality amongst all malignancies. Different apoptotic biomarkers were utilized to evaluate the severity and progression of cancer. Survivin is a cancer gene that is silenced in differentiated tissues. It is used as a valid predictor for cancer initiation and for monitoring the response to treatment. Chemical induction of cancer could be attempted using different compounds as DMBA and 4NQO. 4NQO is a water soluble quinolone and is considered as a potent tumor inducer in oral cavity. Biological therapy using natural herbs and products is an effective treatment modality for many types of cancer. Propolis extract is a bee-metabolized resinous substance possessing multiple valuable biological properties. **Objective:** The present study was conducted to evaluate the anti-carcinogenic effect of bio-propolis against cancer tongue induced in rats by administration of 4NQO. **Materials & Methods:** A total of 30 mature rats were divided into three groups: Group I (control group), Group II (cancer group) and Group III (propolis-treated group). 4NQO was administrated in groups II and III for 20 weeks, then group III received propolis for 4 weeks. By the end of the study period all rats were sacrificed and tongue tissues were excised for biochemical analysis and histopathological examination. **Results:** propolis-treated group showed a significant decrease in levels of survivin, MDA, IL-6 and TNF- α compared with cancer group. The treatment also resulted in a significant increase in SOD and GSH levels. Histopathological examination revealed invasion of malignant epithelial cells to the underlying lamina propria in the cancer group, while propolis-treated group showed moderate dysplastic changes in the surface epithelium with no invasion to the basement membrane. **Conclusion:** our results suggested that propolis exerts potent antioxidant, anti-inflammatory and anti-proliferative effects. Thus, we concluded that propolis could be considered as a promising adjuvant therapy for oral cancer.

INTRODUCTION

Cancers of the oral cavity and oropharynx are the sixth most common cancer in the world (Warnakulasuriya, 2009). The World Health Organization (WHO) reported oral cancer as having one of the highest mortality ratios amongst all malignancies (Stewart and Wild, 2014). According to the clinicopathological characteristics "oral cancer" can be categorized into carcinomas of oral cavity proper, carcinomas of the vermilion border of the lip and carcinomas of the oropharynx (Saman, 2012).

Development of cancer in humans is a multistep process. Gene mutations lead to neoplastic transformation (Ashkenazi *et al.*, 2008). Mutated genes will result in cells with damaged DNA proliferating at an uncontrolled

Open Access Journal

Published BY AENSI Publication

© 2016 AENSI Publisher All rights reserved

This work is licensed under the Creative Commons Attribution International License (CC BY).

<http://creativecommons.org/licenses/by/4.0/>



Open Access

To Cite This Article: Lawahez El. M. Ismail, Nevien M. Ahmed, Heba A. Shawky., Anti-Carcinogenic Effect of Bio-Propolis on Chemically Induced Tongue Cancer in Albino Rats. *Aust. J. Basic & Appl. Sci.*, 10(8): 173-180, 2016

rate. These cells are unable to neither repairing DNA damage nor undergoing apoptosis (Elmore, 2007). When mutated cell divides, it is capable of passing mutations to all of its progeny. The cellular and molecular changes resulting in cancer development are intervened by different endogenous and exogenous stimuli (Fulda *et al.*, 2010). Reactive oxygen species (ROS) are crucial stimuli in both initiation and progression of carcinogenesis (Durackova, 2010). ROS produce oxidative damage to the tissues and they are thus counteracted in all human cells by an extensive antioxidant defense mechanism. Therefore, the pro-oxidant-antioxidant imbalance can lead to oxidative damage resulting in cancer development (Benedetti *et al.*, 2015).

Apoptotic biomarkers are used to assess disease extent and severity and to predict the response to various treatments (Banin Hirata *et al.*, 2014). Survivin is a cancer gene that is silenced in differentiated tissues; it inhibits apoptosis, promotes mitotic division and stimulates angiogenesis (Pennati *et al.*, 2007). Previous studies have demonstrated the abundance of survivin expression in human cancers (Jaiswal *et al.*, 2015). It is capable of down-regulating apoptosis by increasing the resistance of cancer cell to various apoptotic stimuli through caspase-dependent mechanism and also by blocking apoptosis in a caspase-independent fashion (Santa Cruz Guindalini *et al.*, 2013). Thus, survivin is used as a reliable marker to stratify cancer and to predict the response of cancer patients to chemotherapy and radiotherapy (Goričar *et al.*, 2015).

Several carcinogenic materials have been used for chemical induction of cancer in rats. The most widely used materials are 7,12-dimethylbenz (a) anthracene (DMBA) and 4-nitroquinoline 1-oxide (4NQO) (Tanaka and Ishigamori, 2011). 4NQO is a water soluble quinolone and is considered as a potent tumor inducer in oral cavity (Kanojia and Vaidya, 2006). The enzymatic reduction of the 4NQO nitro group results in the production of reactive oxygen species which in turn causes DNA damage (Vitale-Cross *et al.*, 2009).

Different treatment modalities were suggested for oral cancer depending on its site and stage. These modalities included surgical treatment, radiotherapy or chemotherapy (Huang and O'Sullivan, 2013). Nowadays, biological therapy has been proposed for treatment of many types of cancer. It induces the immune system to recognize and kill cancer cells with minimal adverse effects (Segelov *et al.*, 2014). Different plant and animal extracts possessed immune-potentiating and antitumor activity; hence, they could be effective as adjuvant cancer biological therapy (Solowey *et al.*, 2014).

Propolis is a bee-metabolized resinous substance (bee glue) from plant sap and gums (Miguel and Antunes, 2011). Propolis extract contains amino acids, flavonoids, terpenes and cinnamic acid derivatives. Different studies have reported its positive biological properties as antimicrobial, antioxidant, immune-stimulatory and anti-inflammatory effects (Chan *et al.*, 2013). Its anti-inflammatory effect could be attributed to its ability to inhibit both platelet aggregation and eicosanoid synthesis (Chen *et al.*, 2007).

The present study was performed to evaluate biochemically and histopathologically the efficiency of Bee propolis in the treatment of tongue cancer.

MATERIALS AND METHODS

Experimental design:

A total of thirty healthy male Wistar albino rats ageing between 8 to 10 weeks and weighing 200 – 250 gm, were obtained from the animal house of Medical Research Institute, Alexandria University. They were maintained under controlled conditions of temperature (24 ± 2 °C), light–dark periods of 12 hours and with free access to water and commercial diet. The international guiding principles for biomedical research involving animals were adopted (The Development of Science-based Guidelines for Laboratory Animal Care, 2004).

The animals were divided into 3 groups, ten rats each.

Group I (Control group): normal rats.

Group II (Cancer group): Rats received 50 ppm 4NQO (Sigma Aldrich, St. Louis, USA) daily in drinking water for 20 weeks.

Group III (Propolis group): After 20 weeks of receiving 4NQO, rats were treated by 1 ml/day of aqueous solution of Bio-Propolis (Sigma Pharmaceutical Industries (S.P.I.). For: International Business Establishment (IBE) Pharma), 300mg/Kg/day (Dornelas *et al.*, 2014) for four weeks.

By the end of the experimental period, the rats were sacrificed by an overdose intra-peritoneal injection of 100 mg/kg Phenobarbital sodium (West Ward Pharm., USA). The tongues were longitudinally bisected for the assessment of biochemical parameters and histopathological examinations.

Biochemical analysis:

Tissue samples for biochemical analysis were stored at -45°C in a deep freeze until analysis.

Immunohistochemical assays:

Rat survivin ELISA kit (MyBioSource, Inc. California, USA.) a double-antibody sandwich enzyme-linked immunosorbent assay (ELISA) was used to assess the level of rat survivin in tissue homogenate after preparation according to the manufacturer's instructions (Lladser *et al.*, 2011).

Cytokines assays:

Cytokine production was determined by enzyme-linked immunosorbent assay (ELISA) using commercial kits according to the manufacturer's instructions. IL-6 and TNF- α levels were measured using rat ELISA kits (cloud clone corp.-SEA079 Ra, USA). The plates were read at 450 nm using the CA-2000 ELISA micro-plate reader (CIOM Medical Co., Ltd., China). Cytokine levels in the samples were calculated from standard curves of recombinant cytokines using a linear regression method (Yazar *et al.*, 2011)

Lipid peroxidation and tissue antioxidant enzymes:

Lipid peroxidation was determined by quantifying malondialdehyde (MDA) that formed in terms of thiobarbituric acid reactive substances (TBARS). Tissue samples were homogenized in Tris-HCl buffer (0.01 μ M, pH 7.4) using a REMI homogenizer (REMI Motor, Bombay, India) to generate a 10% homogenate. The homogenate was subjected to estimation of MDA according to (Ohkawa *et al.*, 1979). Reduced glutathione (GSH) in tissue homogenate was determined calorimetrically by the method modified by (Bulaj *et al.*, 1998). Superoxide dismutase (SOD) activities were assayed in the tissue homogenates by the method of (Misra and Fridovich, 1972).

Histopathological analysis:

Histopathological evaluation was performed under light microscope. Specimens were immediately fixed in 10% neutral formalin for 48 hours. Then they were dehydrated in ascending grades of alcohol and embedded in paraffin. Histological sections of 5 μ m thickness were obtained and stained with hematoxylin and eosin stain according to the conventional method (Bashkar, 1990).

Statistical analysis of the data:

Data were fed to the computer and analyzed using IBM SPSS software package version 20.0. Results were expressed as mean \pm standard deviation (SD). Analysis of variance (ANOVA) was used for comparing the three studied groups. Significance of the obtained results was judged at the 5% level.

Result:**Biochemical Results:****Expression of survivin in tongue tissue:**

4NQO produced cancer after 20 weeks. Survivin level was detected by ELISA. In cancer group, survivin level was significantly elevated compared with control group ($p < 0.001$), while treatment with propolis for four weeks showed significant decrease in the survivin level compared with cancer group ($p < 0.001$) (Table 1).

Inflammatory markers:

Cancer group exhibited significant increase ($p < 0.001$) in levels of both IL-6 and TNF- α compared with control group. Treatment with propolis showed a significant decrease ($p < 0.001$) compared with cancer group (Table 1).

Oxidative stress markers:

Cancer group showed a significant increase ($p < 0.001$) in levels of tongue tissue MDA and a significant decrease ($p < 0.001$) in both tongue tissue SOD and GSH levels compared with the control group. Whereas, treatment with propolis showed a significant decrease ($p < 0.001$) in MDA and a significant increase in SOD and GSH levels ($p = 0.001$, $p < 0.001$ respectively) (Table 2).

Table 1: Comparison of survivin, IL-6 and TNF-alpha levels between the three studied groups

	Control (n = 10)	Cancer (n = 10)	Propolis-treated (n = 10)	p
Survivin (pg/mL)	1.54 \pm 0.58	516.10 ^a \pm 92.80	280.30 ^b \pm 25.82	<0.001*
IL-6 (pg/mL)	1.54 \pm 0.21	7.44 ^a \pm 1.01	3.14 ^b \pm 0.99	<0.001*
TNF-alpha (pg/mL)	11.69 \pm 2.20	35.44 ^a \pm 4.55	22.96 ^{ab} \pm 3.77	<0.001*

Normally distributed data was expressed in mean \pm SD and was compared using F test (ANOVA)

*: Statistically significant at $p \leq 0.05$

a: significant with control, b: significant with cancer

Table 2: Comparison of Oxidative stress parameters between the three studied groups

	Control (n = 10)	Cancer (n = 10)	Propolis-treated (n = 10)	p
MDA (mmol/mg protein)	0.92 \pm 0.24	6.14 ^a \pm 0.94	2.85 ^b \pm 0.30	<0.001*
SOD (units/mg protein)	3.13 \pm 0.43	2.53 ^a \pm 0.35	3.39 ^b \pm 0.56	0.001*
GSH (μ g/mg protein)	0.12 \pm 0.0	0.09 ^a \pm 0.00	0.11 ^b \pm 0.00	<0.001*

Normally distributed data was expressed in mean \pm SD and was compared using F test (ANOVA)

*: Statistically significant at $p \leq 0.05$

a: significant with control, b: significant with cancer

Histopathological Findings:**Group I (Control group):**

Histopathological examination of control group showed that the oral mucosa covering the ventral surface of the tongue was composed of keratinized stratified squamous epithelium and thin underlying lamina propria containing collagen fibers and small blood vessels. Groups of well-formed striated muscles were also noticed beneath the lamina propria while neither inflammatory cell infiltration nor congested blood vessels were observed (Fig. 1, 2).

Group II (Cancer group):

The examination revealed invasive squamous cell carcinoma described histologically as invasion of malignant epithelial cells to the underlying lamina propria. The proliferating malignant epithelial cells formed cell nests, epithelial pearls as well as keratin pearls. The connective tissue stroma surrounding the proliferating malignant epithelial cells contained a large amount of chronic inflammatory cells (Fig.3, 4).

Group III (Propolis-treated group):

It showed moderate dysplastic changes in the surface epithelium such as cellular pleomorphism, increase in nuclear cytoplasmic ratio, hyper-chromatic nuclei and drop shaped rete process. These dysplastic changes were extending to the middle third of the epithelium and located in basal and para-basal layers. There was no invasion to the basement membrane (Fig. 5, 6).

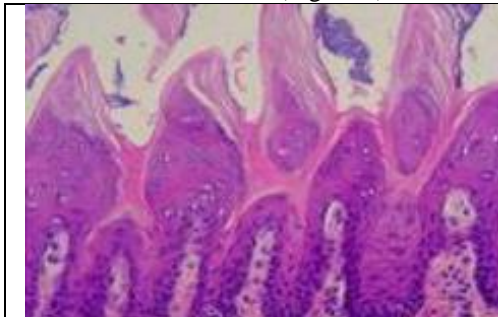


Fig. 1: photomicrograph of Group I (control) showing normal keratinized stratified squamous epithelium and thin underlying lamina propria (H&E) x100.

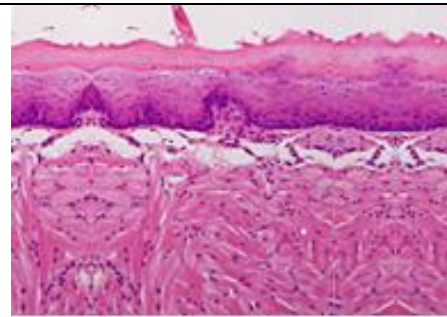


Fig. 2: photomicrograph of Group I (control) revealing normal keratinized stratified squamous epithelium and thin underlying lamina propria containing collagen fibers and small blood vessels as well as groups of well-formed striated muscles forming the mucosal lining epithelium of the border of the tongue (H&E) x100.

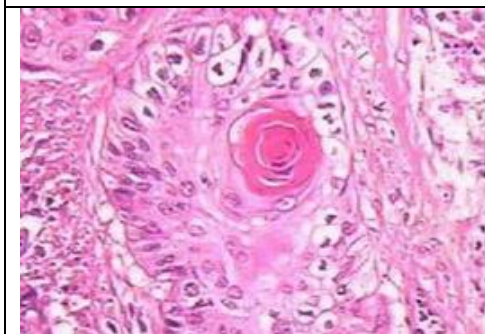


Fig. 3: Photomicrograph of Group II (cancer) revealing invasion of malignant epithelial cells to the underlying connective tissue stroma forming epithelial pearls surrounded by a large number of chronic inflammatory cells (H&E) x200.

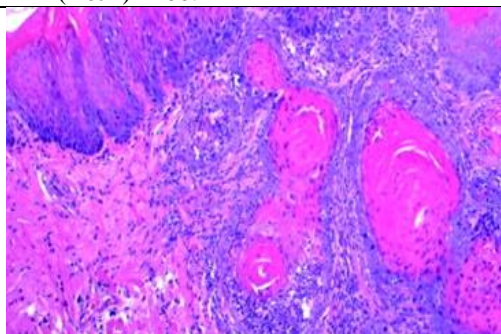


Fig. 4: Photomicrograph of Group II (cancer) showing invasion of malignant epithelial cells to the underlying connective tissue stroma with the formation of cell nests as well as keratin pearls. The surrounding connective tissue showed a large number of chronic inflammatory cells (H&E) x200.

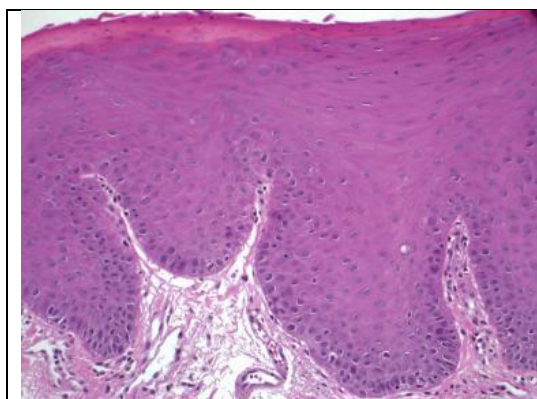


Fig. 5: Photomicrograph of Group III (propolis-treated group) showing moderate dysplastic changes in the surface epithelium such as cellular pleomorphism and nuclear hyperchromatin (H&E) x 200.

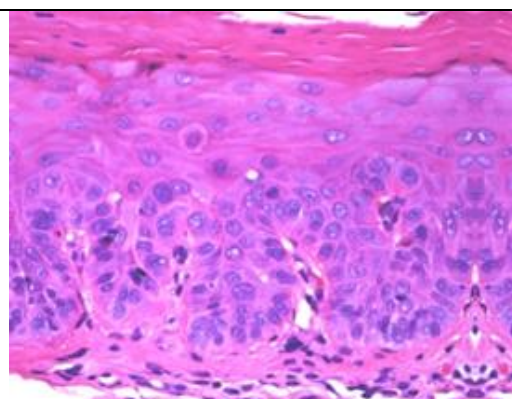


Fig. 6: Photomicrograph of Group III (propolis-treated group) showing moderate dysplastic changes in the covering stratified squamous epithelium such as cellular pleomorphism, nuclear hyperchromatin and increased nuclear cytoplasmic ratio reaching to the middle third of surface epithelium (H&E) x 200.

Discussion:

Oral cancer is a public health problem. The great interest in the use of natural substances in treatment of oral cancer is due to their chemo-preventive properties with fewer adverse effects (Kaur *et al.*, 2009).

In the present study rats with chemically induced tongue cancer received honey bee Bio-Propolis for 4 weeks. Survivin apoptotic marker was used to monitor the changes in apoptotic levels in normal and cancer tissue, as well as cancer tissues which received propolis therapy. ELIZA was used to measure the survivin level; our results showed a significant increase in survivin level from 1.54 ± 0.58 in control group to 516.10 ± 92.80 in cancer group. These results were in accordance with (Atlasi *et al.*, 2009) who concluded that the level of survivin expression was significantly higher in neoplastic compared with non-neoplastic tissues and that it showed significant correlation with tumor invasiveness. Moreover, (Kiu *et al.*, 2014) examined the expression of survivin in cancer cell lines using quantitative real-time polymerase chain reaction (PCR), results showed an increase in the cancer cell survivin gene expression from 3.2 to 16.7 folds. On the other hand, our results revealed that there was a significant decrease in survivin in the cancer group treated by propolis. These results agree with those of (Szliszka and Krol, 2013) who proved that polyphenols isolated from propolis, was able to augment TNF-related apoptosis inducing ligand (TRAIL)-mediated apoptotic death in cancer cells and to down-regulate survivin expression. This is attributed to the ability of propolis to speed up apoptosis of cancer cells (Vagish Kumar, 2014). It was demonstrated that propolis increases the apoptosis of cancer cells through suppression of cell survival pathways such as the AKT signaling pathway (Drago *et al.*, 2013). In addition, (Szliszka *et al.*, 2009) reported that propolis can initiate apoptosis in cancer cells through both intrinsic and extrinsic pathways. The interaction between pro- and anti-apoptotic members of the Bcl-2 family proteins controls the intrinsic apoptotic pathway mediated by the mitochondria. Apoptosis is mainly regulated by the ratio between Bcl-2 and Bax genes rather than the level of each Bcl-2 family protein alone (Tait and Green, 2010). Moreover both Bax/Bcl-2 ratio and the p53 gene expression increased after $100\mu\text{g/mL}$ of propolis administration which resulted in triggering apoptosis of human bladder cancer cells (Begnini *et al.*, 2014).

In the current study significant increase in the levels of IL-6 and of TNF- α was observed in the cancer group compared with the control group. These results were in convenience with (Lotfi *et al.*, 2015) who proved that IL-6 level was significantly higher in patients with oral squamous cell carcinoma and with (Stanilov *et al.*, 2012) who demonstrated the overproduction of TNF- α in cancer patients. TNF- α can stimulate DNA damage and mutations and hence tumor initiation through the production of genotoxic molecules as ROS (Reuter *et al.*, 2010). In addition, (Kabel, 2014) reported that TNF- α induces genes encoding nuclear factor kappa B (NF- κ B)-dependent antiapoptotic molecules which results in increasing tumor cell survival. Moreover, our study revealed a significant decrease of both IL-6 and TNF- α cytokines in the propolis-treated group compared with the untreated cancer group. These results agree with (Wu *et al.*, 2013) who reported that propolis affects inflammatory cell activity and inhibits TNF- α and IL-6. Similarly, (Stanilov *et al.*, 2012; Funakoshi-Tago *et al.*, 2015) proved that propolis flavonoids can significantly down-regulate the production of IL-6 and TNF- α via inhibition of expression of their inflammatory genes in bone marrow-derived mast cells and also through inhibition of NF- κ B.

Regarding lipid peroxidation, the current study revealed a significant elevation in MDA level in cancer group compared with the control group. This was in accordance with (Shetty *et al.*, 2014) who denoted an elevation in salivary MDA in subjects with oral squamous cell carcinoma and with (Malathi *et al.*, 2011) who found a higher level of the plasma levels of MDA in patients with head and neck cancer. The increased MDA level in cancer group is due to the reported fact that cancer cells produce large amount of free radicals that leads to elevation of the lipid peroxidation (Ayala *et al.*, 2014). Our result showed that treatment with propolis decreased the levels of MDA and these results supported those of (Padmavathi *et al.*, 2006) who demonstrated a marked decrease in level of MDA in rat breast cancer after treatment with propolis.

Concerning the antioxidant enzymes, the present study showed a decrease in levels of both SOD and GSH in cancer group compared with the control group while treatment with propolis significantly increased the levels of both enzymes compared with the cancer group. The increase of antioxidant enzyme activities such as SOD and GSH is considered as a protective mechanism against free radical production and lipid peroxidation occurring in cancer group (Weinberg and Chandel, 2009). These results confirmed those of (El Fatoh *et al.*, 2014) who concluded that propolis possessed potent anti-oxidant effect.

Histopathological results of the current study revealed that the mucosal epithelium lining of the tongue border of Group I (control) appeared as normal keratinized squamous epithelium with thin underlying lamina propria containing collagen fibers and small blood vessels with no inflammatory cell infiltration or congested blood vessels. While, in Group II (cancer) after receiving 4NQO for 20 weeks; invasive squamous cell carcinoma was observed which appeared as proliferation of malignant epithelial cells into the underlying connective tissue forming epithelial pearls and cell nests surrounded by large number of chronic inflammatory cells indicating the malignant transformation of covering epithelium. These findings agree with (Schoop *et al.*, 2009; Martinez and Andres, 2012; Li *et al.*, 2013) who clarified the carcinogenic potential of 4NQO.

The propolis-treated group in the current work appeared histopathologically as moderate dysplasia limited to the middle third of the covering epithelium. Similar to (Cavalcante *et al.*, 2011) who evaluated the effect of green propolis on epithelial dysplasia in rat tongues and found that propolis-treated group showed morpho-architectural changes limited to the basal and parabasal tissue with mild hyper-chromatic cytological alterations in the same layers. These findings proved the positive effect of propolis extract in suppressing the dysplastic changes in the epithelial layer and inhibiting the proliferation of invasive carcinoma which suggested the beneficial role of propolis against chemically-induced carcinogenesis in rats.

Thus, our results illustrate the anti-carcinogenic effects of propolis which agrees with (Pereira-Filho *et al.*, 2014; Khacha-anada *et al.*, 2013; kubina *et al.*, 2015) who confirmed the anti-proliferative activity of propolis in different carcinoma cells.

Conclusion:

Based on the previous biochemical and histopathological results, we concluded that propolis could be used as a promising adjuvant therapy for oral cancer based on its strong antioxidant, anti-inflammatory and anti-proliferative properties.

REFERENCES

- Ashkenazi, R., S.N. Gentry and T.L. Jackson, 2008. Pathways to Tumorigenesis—Modeling Mutation Acquisition in Stem Cells and Their Progeny. *Neoplasia*, 10(11): 1170-1182.
- Atlasi, Y., S.J. Mowla and S.A. Ziaee, 2009. Differential expression of survivin and its splice variants, survivin-DeltaEx3 and survivin-2B, in bladder cancer. *Cancer Detection and Prevention*, 32(4): 308-313.
- Ayala, A., M.F. Muñoz and S. Argüelles, 2014. Lipid Peroxidation: Production, Metabolism, and Signaling Mechanisms of Malondialdehyde and 4-Hydroxy-2-Nonenal. *Oxidative medicine and cellular longevity*, pp: 360438.
- Banin Hirata, B.K., J.M. Oda, R. Losi Guembarovski., C.B. Ariza, C.E. de Oliveira and M. A. Watanabe, 2014. Molecular markers for breast cancer: prediction on tumor behavior. *Disease Markers*, pp: 513158.
- Bashkar, S.N., 1990. *Orban's Oral Histology and Embryology*: 11th Ed. Baltimore, Boston, Chicago, London, Philadelphia, Sydney, Toronto: Mosby st. Louis. 365, 339-41, 349-50, 470-473.
- Begnini, K.R., P.M. Moura de Leon, H. Thurow, E. Schultze, V.F. Campos, F. Martins Rodrigues, S. Borsuk, O.A. Dellagostin, L. Savegnago, S. Roesch-Ely, M. Moura, F.F. Padilha, T. Collares, J.A. Pêgas Henriques and F.K. Seixas, 2014. Brazilian red propolis induces apoptosis-like cell death and decreases migration potential in bladder cancer cells. *Evidence Based Complementary and Alternative Medicine*, pp: 639856.
- Benedetti, S., B. Nuvoli, S. Catalani and R. Galati, 2015. Reactive oxygen species a double-edged sword for mesothelioma. *Oncotarget*, 10;6(19):16848-16865.
- Bulaj, G., T. Kortemme and D.P. Goldenberg, 1998. Ionization: Reactivity relationships for cysteine thiols in polypeptides. *Biochemistry*, 37: 8965-8972.

Cavalcante, D.R., P.S. Oliveira, S.M. Góis, A.F. Soares, J.C. Cardoso, F.F. Padilha and R.L. Albuquerque, 2011. Effect of green propolis on oral epithelial dysplasia in rats. *Brazilian Journal of Otorhinolaryngology*, 77(3): 278-284.

Chan, G.C., K.W. Cheung and D.M. Sze., 2013. The immunomodulatory and anticancer properties of propolis. *Clinical Review in Allergy & Immunology*, 44(3): 262-273.

Chen, T.G., J.J. Lee, K.H. Lin, C.H. Shen, D.S. Chou and J.R. Sheu, 2007. Antiplatelet activity of caffeic acid phenethyl ester is mediated through a cyclic GMP-dependent pathway in human platelets. *Chinese Journal of Physiology*, 50: 212-216.

Dornelas, C.A., B.C. Cavalcanti, H.I. Magalhães, F.V. Jamaru, F.N. Furtado, C. Juanes Cde, O. MeloNde and, M.O. Moraes, 2014. Potential chemoprotective effects of green propolis, L-lysine and celecoxib on bone marrow cells and peripheral blood lymphocytes of Wistar rats subjected to bladder chemical carcinogenesis. *Acta Cirurgia Brasileira*, 29(7): 423-428.

Drago, E., M. Bordonaro, S. Lee, W. Atamna and D.L. Lazarova, 2013. Propolis Augments Apoptosis Induced by Butyrate via Targeting Cell Survival Pathways. *PLOS ONE*, 8(9): e73151.

Durackova, Z., 2010. Some current insights into oxidative stress. *Physiological Research*, 59: 459-469.

El Fatoh, M.F., M.A. Kamel, A. Mohammed and E.A. Hussein, 2014. Anticarcinogenic and Antioxidant Effects of Propolis Aqueous extract against Ehrlich Ascites Carcinoma (EAC) Cells bearing Mice. *International Journal of Pharmaceutical Sciences*, 4(4): 606-610.

Elmore, S., 2007. Apoptosis: A Review of Programmed Cell Death. *Journal of Toxicological Pathology*, 35(4): 495-516.

Fulda, S., A.M. Gorman, O. Hori and A. Samali, 2010. Cellular stress responses: cell survival and cell death. *International journal of Cell Biology*, pp: 214074.

Funakoshi-Tago, M., K. Okamoto, R. Izumi, K. Tago, K. Yanagisawa, Y. Narukawa, F. Kiuchi, T. Kasahara and H. Tamura, 2015. Anti-inflammatory activity of flavonoids in Nepalese propolis is attributed to inhibition of the IL-33 signaling pathway. *International Immunopharmacology*, 25(1): 189-198.

Goričar, K., V. Kovač, A. Franko, M. Dodič-Fikfak and V. Dolžan, 2015. Serum Survivin Levels and Outcome of Chemotherapy in Patients with Malignant Mesothelioma. *Disease Markers*, pp: 316739.

Huang, S.H. and B.O'Sullivan, 2013. Oral cancer: Current role of radiotherapy and chemotherapy. *Medicina Oral, Patología Orally Cirugía Bucal*, 18(2): e233-e240.

Jaiswal, P.K., A. Goel and R.D. Mittal, 2015. Survivin: A molecular biomarker in cancer. *Indian Journal of Medical Research*, 141(4): 389-397.

Kabel, A.M., 2014. Relationship between Cancer and Cytokines. *Journal of Cancer Research and Treatment*, 2(2): 41-43.

Kanojia, D. and M.M. Vaidya, 2006. 4-nitroquinoline-1-oxide induced experimental oral carcinogenesis. *Oral Oncology*, 42(7): 655-667.

Kaur, M., C. Agarwal and R. Agarwal, 2009. Anticancer and Cancer Chemopreventive Potential of Grape Seed Extract and Other Grape-Based Products. *Journal of nutrition*, 139(9): 1806S-1812S.

Khacha-ananda, S., K. Tragoolpua, P. Chantawannakul and Y. Tragoolpua, 2013. Antioxidant and anti-cancer cell proliferation activity of propolis extracts from two extraction methods. *Asian Pacific Journal of Cancer Prevention*, 14(11): 6991-6995.

Kiu, K.T., T.S. Hwang, H.Y. Hsieh, C.H. Shen, Y.H. Wang and G.D. Juang, 2014. Expression of survivin in bladder cancer cell lines using quantitative real-time polymerase chain reaction. *Urological Science*, 25(1): 19-21.

Kubina, R., A. Kabała-Dzik, A. Dziedzic, B. Bielec, R.D. Wojtyczka, R.J. Bułdak, M. Wszyńska, B. Stawiarska-Pięta and E. Szaflarska-Stojko, 2015. The Ethanol Extract of Polish Propolis Exhibits Anti-Proliferative and/or Pro-Apoptotic Effect on HCT 116 Colon Cancer and Me45 Malignant Melanoma Cells In Vitro Conditions. *Advances in Clinical and Experimental Medicine*, 24(2): 203-212.

Li, J., F. Liang, D. Yu, H. Qing and Y. Yang, 2013. Development of a 4-nitroquinoline-1-oxide model of lymph node metastasis in oral squamous cell carcinoma. *Oral Oncology*, 49(4): 299-305.

Lladser, A., C. Sanhueza, R. Kiessling and A.F. Quest, 2011. Is survivin the potential Achilles' heel of cancer? *Advances in Cancer Research*, 111: 1-37.

Lotfi, A., N. Shahidi, G. Bayazian, Sh. Abdollahi Fakhim, R. Estakhri, A. Esfahani and N. Rezvan, 2015. Serum Level of Interleukin-6 in Patients with Oral Tongue Squamous cell Carcinoma. *Iranian Journal of Otorhinolaryngology*, 27(80): 207-211.

Malathi, M., M. Vijay and A.R. Shivashankara, 2011. The Role of Oxidative Stress and the Effect of Radiotherapy on the Plasma Oxidant-Antioxidant Status In Head And Neck Cancer. *Journal of clinical and diagnostic research*, 5(2): 249-251.

Martinez, R. and C. Andrés, 2012. 4NQO Carcinogenesis: A Model of Oral Squamous Cell Carcinoma. *International Journal of Morphology*, 30(1): 309-314.

Miguel, M.G. and M.D. Antunes, 2011. Ispropolis safe as an alternative medicine? *Journal of Pharmacy & Bioallied Sciences*, 3(4):479-495.

Misra, H.P. and I. Fridovich, 1972. The role of superoxide anion in the autoxidation of epinephrine and a simple assay for superoxide dismutase. *Journal of Biological Chemistry*, 247: 3170-3175.

Ohkawa, H., N. Ohishi and K. Yagi, 1979. Assay for lipid peroxidation in animal tissues by thiobarbituric acid reaction. *Annals of Biochemistry*, 95: 351-358.

Padmavathi, R., P. Senthilnathan, D. Chodon and D. Sakthisekaran, 2006. Therapeutic effect of paclitaxel and propolis on lipid peroxidation and antioxidant system in 7,12 dimethyl benz (a) anthracene-induced breast cancer in female Sprague Dawley rats. *Life Sciences*, 78(24): 2820-2825.

Pennati, M., M. Folini and N. Zaffaroni, 2007. Targeting survivin in cancer therapy: fulfilled promises and open questions. *Carcinogenesis*, 28(6):1133-1139.

Pereira-Filho, R.N., F.S. Batista, D.R. Ribeiro, G.C.F.P. Melo, Reis, A.U. Melo, M.Z. Gomes, J.C. Cardoso and R.L. Albuquerque Júnior, 2014. Chemopreventive Effect of Brazilian Green Propolis on Experimental Dermal Carcinogenesis in Murine Model. *International Journal of Morphology*, 32(2): 522-530.

Reuter, S., S.C. Gupta, M.M. Chaturvedi and B.B. Aggarwal, 2010. Oxidative stress, inflammation, and cancer: How are they linked? *Free radical biology & medicine*, 49(11): 1603-1616.

Saman, D.M., 2012. A review of the epidemiology of oral and pharyngeal carcinoma: update. *Head & Neck Oncology*, 4: 1.

Santa Cruz Guindalini, R., M.C. Mathias Machado and B. Garicochea, 2013. Monitoring survivin expression in cancer: implications for prognosis and therapy. *Molecular Diagnosis and Therapy journal*, (6): 331-342.

Schoop, R.L., M.H. Noteborn and R.J. Baatenburg de Jong, 2009. A mouse model for oral squamous cell carcinoma. *Journal of Molecular Histology*, 40(3): 177-181.

Segelov, E., D. Chan, J. Shapiro, T.J. Price, C.S. Karapetis, N.C. Tebbutt and N. Pavlakakis, 2014. The role of biological therapy in metastatic colorectal cancer after first-line treatment: a meta-analysis of randomised trials. *British Journal of Cancer*, 111(6): 1122-1131.

Shetty, S.R., S. Babu, S. Kumari, P. Shetty, S. Hegde and R. Castelino, 2014. Status of salivary lipid peroxidation in oral cancer and precancer. *Indian Journal of Medical Pediatric Oncology*, 35(2): 156-158.

Solowey, E., M. Lichtenstein, S. Sallon, H. Paavilainen, E. Solowey and H. Lorberboum-Galski, 2014. Evaluating Medicinal Plants for Anticancer Activity. *The Scientific World Journal*, pp: 721402.

Stanilov, N.S., Z.G. Dobrova and S.A. Stanilova, 2012. Higher TNF-alpha production detected in colorectal cancer patients monocytes. *Biotechnology and Biotechnological Equipment*, 26(1):107-110.

Stewart, B.W. and C.P. Wild, 2014. *World Cancer Report 2014*. International Agency for Research on Cancer (IARC) Nonserial Publication.

Szliszka, E., Z.P. Czuba, M. Domino, B. Mazur, G. Zydowicz and W. Krol, 2009. Ethanolic extract of propolis (EEP) enhances the apoptosis-inducing potential of TRAIL in cancer cells. *Molecules journal*, 14(2): 738-754.

Szliszka, E. and W. Krol, 2013. Polyphenols Isolated from Propolis Augment TRAIL-Induced Apoptosis in Cancer Cells. *Evidenced Based Complementary and Alternative Medicine*, pp: 731940.

Tait, S.W. and D.R. Green, 2010. Mitochondria and cell death: outer membrane permeabilization and beyond. *Nature Reviews Molecular Cell Biology*, 11(9): 621-632.

Tanaka, T. and R. Ishigamori, 2011. Understanding carcinogenesis for fighting oral cancer. *Journal of Oncology*, pp: 603740.

The Development of Science-based Guidelines for Laboratory Animal Care. *Proceedings of the November, 2003 International Workshop National Research Council (US) Institute for Laboratory Animal Research*. Washington (DC): National Academies Press (US); 2004. ISBN-10: 0-309-09302-3

Vagish Kumar, L.S., 2014. Propolis in Dentistry and Oral Cancer Management. *North American Journal of Medical Sciences*, 6(6): 250-259.

Vitale-Cross, L., R. Czerninski, P. Amornphimoltham, V. Patel, A.A. Molinolo and J.S. Gutkind, 2009. Chemical carcinogenesis models for evaluating molecular-targeted prevention and treatment of oral cancer. *Cancer Prevention Research (Phila)*, 2(5): 419-422.

Warnakulasuriya, S., 2009. Global epidemiology of oral and oropharyngeal cancer. *Oral Oncology*, 45(4-5): 309-316.

Weinberg, F. and N.S. Chandel, 2009. Reactive oxygen species-dependent signaling regulates cancer. *Cellular and Molecular Life Sciences*, 66(23): 3663-3673.

Wu, Z., A. Zhu, F. Takayama, R. Okada, Y. Liu, Y. Harada, S. Wu and H. Nakanishi, 2013. Brazilian green propolis suppresses the hypoxia-induced neuroinflammatory responses by inhibiting NF- κ B activation in microglia. *Oxidative Medicine and Cellular Longevity*, pp: 906726.

Yazar, M., Y. Deger and F. Yur, 2011. Serum Cytokine and Vitamin Levels in Experimental Diabetic Rats. *Journal of Animal and Veterinary Advance*, 10(5): 622-626.